



Platinum Priority – Incontinence

Editorial by Drogo K. Montague on pp. 934–935 of this issue

Prospective Evaluation of the Functional Sling Suspension for Male Postprostatectomy Stress Urinary Incontinence: Results after 1 Year

Ricarda M. Bauer^{*}, Margit E. Mayer, Christian Gratzke, Irina Soljanik, Alexander Buchner, Patrick J. Bastian, Christian G. Stief, Christian Gozzi

Urological Department, Ludwig-Maximilian-University, Munich, Germany

Article info

Article history:

Accepted July 21, 2009

Published online ahead of print on July 29, 2009

Keywords:

Retrourethral transobturator sling
 Functional sling
 Radical prostatectomy
 Male stress urinary incontinence
 Male sling
 Postprostatectomy incontinence

Abstract

Background: Although surgical techniques for radical prostatectomy (RP) have been refined significantly, a significant number of patients still suffer from persisting postprostatectomy stress urinary incontinence (SUI). In recent years, various minimally invasive sling systems have been investigated as treatment options for such incontinence.

Objective: The aim of the study was the prospective evaluation of the efficacy of the retrourethral transobturator sling for the functional treatment of male SUI after RP.

Design, setting, and participants: The study documents a single-centre prospective evaluation of the outcome of 124 patients with mild to severe SUI following RP in whom an AdVance sling was implanted between February 2006 and September 2008.

Measurements: All patients were comprehensively evaluated preoperatively and after 6 mo and 1 yr regarding daily pad use, 1-h and 24-h pad tests, residual urine, uroflowmetry, Incontinence Quality of Life Scale (I-QOL) score, and Incontinence Questionnaire–Urinary Incontinence Short Form (ICIQ–UI SF) score. Data were collected prospectively.

Results and limitations: After 6 mo, a cure rate (no pads or one dry security pad) of 55.8%, an improved rate (one to two pads or pad reduction $\geq 50\%$) of 27.4%, and a failure rate of 16.8% were observed. After 1 yr, the cure rate was 51.4%, the improved rate was 25.7%, and the failure rate was 22.9%. Daily pad use and pad weight decreased significantly postoperatively. No significant changes were seen in residual urine and flow rate. Quality-of-life scores improved significantly. Postoperative acute urinary retention was seen in 12.9% of patients. One patient had a local wound infection that was cured with antibiotics. One patient had the sling removed due to misplacement.

Conclusions: The retrourethral transobturator sling is an effective and attractive treatment option for male SUI resulting from RP after 1 yr of implantation.

© 2009 European Association of Urology. Published by Elsevier B.V. All rights reserved.

^{*} Corresponding author: Urological Department, Ludwig Maximilian University, Marchioninistr. 15, 81377 Munich, Germany. Tel. +49 89 7095 0.

E-mail address: Ricarda.Bauer@med.uni-muenchen.de (R.M. Bauer).

1. Introduction

Although surgical techniques for radical prostatectomy (RP) have been refined significantly during the last 20 yr, a significant number of patients still suffer from persisting postprostatectomy stress urinary incontinence (SUI) [1–3]. In recent years, various minimally invasive sling systems have been investigated as treatment options for such incontinence [4–12].

All currently marketed slings for the minimally invasive treatment of male SUI that are implanted in the region of the anterior (bulbar) urethra induce compression of the urethra. The retrourethral transobturator sling offers a noncompressive functional therapeutic approach. It exerts its function on the posterior (membranous) urethra by fixing it into the “normal” anatomic position, thus allowing adequate function of the sphincter, and has been shown not to be efficacious in patients with intrinsic sphincter deficiency [13]. In urethroscopic assessment during perineal elevation, men with postprostatectomy SUI and no intrinsic sphincter deficiency show passive sphincter closure with visible contraction of the whole circumference of the sphincter in comparison to no elevation (ie, *repositioning test*). Additionally, these patients show much stronger and more prolonged sphincter contraction under elevation. The described elevation test for simulation of the sling effect prior to surgery is a nonstandardised test, potentially implying subjective results. However, the effect of the perineal elevation as an indicator for postoperative treatment success is immediately evident and comprehensible for the examiner.

In urodynamic studies, an increase of the membranous urethral length and improvement of the urethral closure pressure were shown without obstruction of the urethra [13]. Results after 3 mo showed a significant cure and improvement rate [13,14]. In the current study, 6-mo and 1-yr results of the retrourethral transobturator sling are presented.

2. Patients and methods

Between February 2006 and September 2008, 124 consecutive patients were treated with the AdVance sling in a prospective, sequential clinical study. Men with mild to severe SUI after RP were included in this study. Sling implantation was performed by three well-trained surgeons.

The time span between RP and sling implantation was at least 6 mo (range: 6–228 mo; mean: 44 mo; median: 32 mo). Thirteen of these patients had received prior adjuvant radiotherapy. Sling implantation was done a minimum of 6 mo after adjuvant radiotherapy.

Patients without previous failed conservative treatment for SUI, patients with prostate-specific antigen recurrence, and patients with detrusor sphincter dyssynergia (DSD) or detrusor overactivity (DO; amplitude >5 cm H₂O in urodynamic study) were excluded from the study.

Patient age was 54–87 yr (median: 69 yr; mean: 68.9 yr). Before sling implantation, all of the patients had received conservative SUI treatments that failed [19]. Twenty patients had received pharmacologic treatment, one patient had received a different sling, and three patients had received an artificial urinary sphincter (AUS). In these patients, the AUS has been explanted due to complications. Seven patients had failed stem cell therapy, seven patients had received bulking agent therapy

without success, and six patients had received both. Stem cell therapy and/or bulking agent therapy was administered at least 6 mo prior to sling implantation.

Comprehensive preoperative work-up was done in every patient and included full urodynamic assessment (to exclude DO or DSD), stress test (cough test), uroflowmetry, ultrasound for residual urine, flexible urethroscopy, and micturition cystography. Micturition cystography was carried out to evaluate the mobility of the bladder and bladder neck. Flexible urethroscopy was performed to evaluate the sphincter function and the mobility of the posterior urethra. During urethroscopy, the “repositioning test” was done to simulate sling function. Repositioning and elevation of the posterior urethra can be achieved by perineal pressure. Patients who showed no sphincter contraction in this test were excluded from the study. Patients with sphincter contraction but not total sphincter closure were included.

Pad tests were performed 1 h and 24 h preoperatively, and daily pad use was assessed. The impact of SUI on quality of life (QoL) was measured preoperatively with scores on the Incontinence Quality of Life Scale (I-QoL) and the Incontinence Questionnaire–Urinary Incontinence Short Form (ICIQ–UI SF) [15,16]. QoL questionnaires were filled out by patients in the office. After 6 mo and 1 yr postoperatively, we examined the patients again in our out-patient office. At those times, daily pad use, 1-h and 24-h pad tests, residual urine, uroflowmetry, I-QoL score, and ICIQ–UI SF score were repeated.

Preoperatively, 19 patients showed mild incontinence (one to two pads per day), 60 patients exhibited moderate incontinence (three to five pads per day), and 34 patients showed severe incontinence (six or more pads per day). Preoperatively, residual urine was ≤100 ml in all but two patients. The cough test with bladder filling of at least 200 ml was positive in all patients. There were 56 patients (49.5%) who had spinal anaesthesia and 57 patients (50.4%) who had general anaesthesia.

Cure rate was defined as no pad use or one pad that was used for security reasons and that stayed dry during the day. “Improved” rate was defined as one to two wet pads or a reduction of pads ≥50%. Treatment was considered a success if patients were either cured or improved.

2.1. Surgical technique

The AdVance sling is a polypropylene monofilament mesh that is self-anchoring due to its woven nature. It is implanted using a transobturator approach via a median perineal incision utilizing a trocar system. The procedure is performed as previously described with some minor changes [13]. The middle part of the sling is fixed with long-term resorbable suture distally on the bulbus such that the bulbus appendix can rotate retrourethraly and cranially to avoid hypermobility. Consequently, the required integrity in the 6 o'clock anastomotic region is regained. After fixation, the sling has to be pulled at both ends to its final position, whereby the membranous urethra is moved into a more proximal position. For correct positioning of the sling, urethroscopy is done after mobilisation of the bulb. By means of urethroscopy, the optimal position and tension for the sling can be readily identified; position and tension are perfect when the sphincter shows passive contraction of the whole circumference. The sling is self-anchoring; however, for three of the first few patients, slippage of the sling was noticed in the first days after surgery. To prevent sling slippage, both ends of the sling are fixed at skin level by making a second skin incision beneath the first one, thereby anchoring the ends of the sling subcutaneously at a 90° angle. After sling implantation, we recommend a second urethroscopy to rule out urethra perforation.

2.2. Statistical analysis

Wilcoxon signed rank test was performed to compare pads per day, flow, residual urine, ICIQ–UI SF score, and I-QoL score at different points in

time before and after sling implantation. The influence of various patient parameters was assessed by performing subgroup analyses using the Mann-Whitney test. Outcomes between 6 mo and 1 yr were compared using Wilcoxon signed rank test.

P values < 0.05 were regarded as significant. All statistical analyses were performed using STATISTICA for Windows (release 8; StatSoft, Tulsa, OK, USA).

3. Results

Eleven of 124 patients were lost to follow-up. These patients, treated in 2006, came from foreign countries and could not be reached for regular follow-ups. The other 113 patients were followed for 6 mo, and 70 patients were followed for 1 yr.

At 6 mo, we achieved a cure rate of 55.8% (63 of 113 patients) and an improvement rate of 27.4% (31 patients). Nineteen patients (16.8%) showed no significant improvement. After 1 yr, we achieved a cure rate of 51.4% (36 of 70 patients) and an improved rate of 25.7% (18 patients). Sixteen patients (22.9%) showed no significant improvement. Three of the improved patients exhibited use of more than 2 pads but also a reduction of pad use $\geq 50\%$; after 6 mo and 1 yr, one patient used 4 pads per day compared to 10 pads before implantation, and two patients required 3 pads per day compared to 6 and 7 pads, respectively, before implantation. No significant worsening of the outcome over time was found ($p = 0.074$).

The subgroup analyses for patients with mild or moderate and severe SUI and of patients with postoperative acute urinary retention (AUR) are shown in Table 1. To test the potential impact of prior treatment, potentially afflicting the sphincter region, a subgroup analysis was performed for patients with pretreatments (radiotherapy, stem cell therapy, bulking agents; Table 1).

After 6 mo as well as after 1 yr, a significant reduction of daily pad usage was achieved (Fig. 1 and Table 2). The 1-h pad test was performed by 96 of 113 patients (84.9%) after 6 mo. The pad weight decreased significantly ($p < 0.001$), from 119.5 g preoperatively to 8.6 g after 6 mo. After 1 yr, only 12 patients performed the 1-h pad test. All of these patients were dry (pad weight: 0 g). In the 24-h pad test, the pad weight was significantly reduced from a mean of 292.2 g before sling implantation to 13.4 g and 16.1 g after

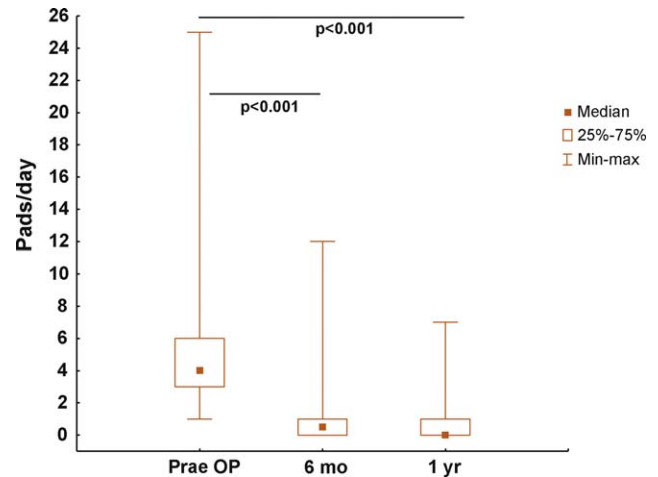


Fig. 1 – Comparison of pad use preoperatively (Prae OP), after 6 months, and after 1 year.

6 mo and 1 yr, respectively. The 24-h pad test was performed by 95 patients (84.1%) after 6 mo and by 58 patients (82.9%) after 1 yr. No significant changes were seen in residual urine and flow rate (Fig. 2).

The flow rate in patients with AUR was significantly lower ($p = 0.030$) after 6 mo, with a preoperative mean flow rate of 21.97 ml/s (median: 19.70 ml/s) and mean flow rate of 17.35 ml/s (median: 16.00 ml/s) after 6 mo. After 1 yr, no statistical significance was seen ($p = 0.260$), with a mean flow rate of 19.33 ml/s (median: 17.00 ml/s). Moreover, residual urine after 6 mo and 1 yr was not significantly different from preoperative residual urine in patients with and without AUR (after 6 mo: $p = 0.361$; after 1 yr: $p = 0.463$).

3.1. Quality of life

Postoperatively, median ICIQ-UI SF score improved significantly, from 17 to 5 after 6 mo and to 4 after 1 yr (Fig. 3). The median I-QoL score also improved significantly, from 59.5 to 95.0 after 6 mo and to 100.0 after 1 yr, respectively (Fig. 4). Additionally, both QoL scores demonstrated a positive increase between 6 mo and 1 yr, although the trend was not significant.

Table 1 – Results of subgroup analyses for patients with mild or moderate and severe stress urinary incontinence (SUI), for patients with and without postoperative acute urinary retention (AUR), and for patients with and without pretreatment (prior radiotherapy, stem cell therapy or bulking agents) after 6 months and 1 year*

	After 6 mo, %	<i>p</i> value	After 1 yr, %	<i>p</i> value
Mild/moderate SUI	87.3 (62.0 + 25.3)	0.130	79.6 (59.2 + 20.4)	0.127
Severe SUI	75.8 (42.4 + 33.4)		71.4 (33.4 + 38.0)	
With AUR	93.8 (68.8 + 25.0)	0.398	72.7 (63.6 + 9.1)	0.388
Without AUR	81.4 (53.6 + 27.8)		78.0 (49.2 + 28.8)	
With pretreatment	82.7 (51.7 + 31.0)	0.860	66.7 (44.4 + 22.3)	0.470
Without pretreatment	83.3 (57.1 + 26.2)		80.8 (53.8 + 27.0)	

Figures in bold type represent the success rate; figures in parentheses represent the dry and improved rate.

* *P* values for statistical difference between the subgroups are given for each time point.

Table 2 – Pad usage as reported by patients prior to sling implantation and after 6 months and 1 year, given as absolute and relative (in parentheses) patient numbers at the respective time point

No. of pads	Preoperative pad usage, n (%)	Pad usage after 6 mo, n (%)	Pad usage after 1 yr, n (%)
0	0 (0)	54 (48)	29 (41)
1 pad for security reasons	0 (0)	9 (8)	7 (10)
1–2	19 (17)	28 (25)	15 (21)
3–4	39 (35)	10 (9)	11 (16)
5–6	30 (27)	7 (6)	5 (7)
7–8	9 (8)	4 (4)	3 (4)
9–10	9 (8)	0 (0)	0 (0)
>10	7 (6)	1 (1)	0 (0)

3.2. Complications

One severe intraoperative complication was observed in our series with 124 patients. In that case, “erosion” of the urethra was diagnosed several weeks after sling implantation. The patient showed worsened incontinence and dysuria. During sling explantation, the erosion could be attributed to a misplaced sling, namely, through the urethra. The patient underwent prior radiotherapy treatment. The sling was removed without further complication.

Postoperative AUR was seen in 16 patients (12.9%). Eleven of these patients (68.75%) had spinal anaesthesia. All of these patients were treated with a suprapubic or transurethral catheter. In all cases, the catheter could be removed after 2–10 wk without further treatment. In 13 of these patients (81.25%), the catheter was removed after at least 3 wk. All patients had residual urine ≤50 ml at time of catheter removal.

One patient had a local wound infection and was treated with oral antibiotics.

4. Discussion

In the present study, 124 patients with mild to severe SUI after RP were treated with the AdVance sling. After 6 mo, 63 of 113 patients (55.8%) were completely dry, achieving

a success rate of 83.2%. After 12 mo, a success rate of 77.1% was obtained, with 36 of 70 patients completely dry (51.4%).

Comparing the patient group with severe SUI only, a success rate of 71.4% was observed after 1 yr. This outcome did not significantly differ from the mild and moderate SUI group (79.6%), suggesting that in clinical practice under real-life conditions, functional sling is effective regardless of the degree of SUI if no intrinsic sphincter deficiency is present.

The results presented after 6 mo and 1 yr are comparable to prior published data for the retourethral transobturator sling with a shorter follow-up of 3 mo [13,14]. Moreover, the success rates are comparable with success rates for other sling systems [4,6,10,17–19], although adjustable systems often required several postoperative adjustments to achieve comparable success rates [6,10,11,17]. Differences in selected patient groups and pretreatment conditions do not allow for a more detailed quantitative comparison of success rates across studies.

The current data illustrate that the retourethral transobturator sling achieves similar results to devices that achieve continence mainly by compression of the urethra. Long-term complications like urethral atrophy, which is known to occur as a result from the permanent high occlusion pressure in AUS, are more likely to occur with compressive sling systems. Prior treatment potentially

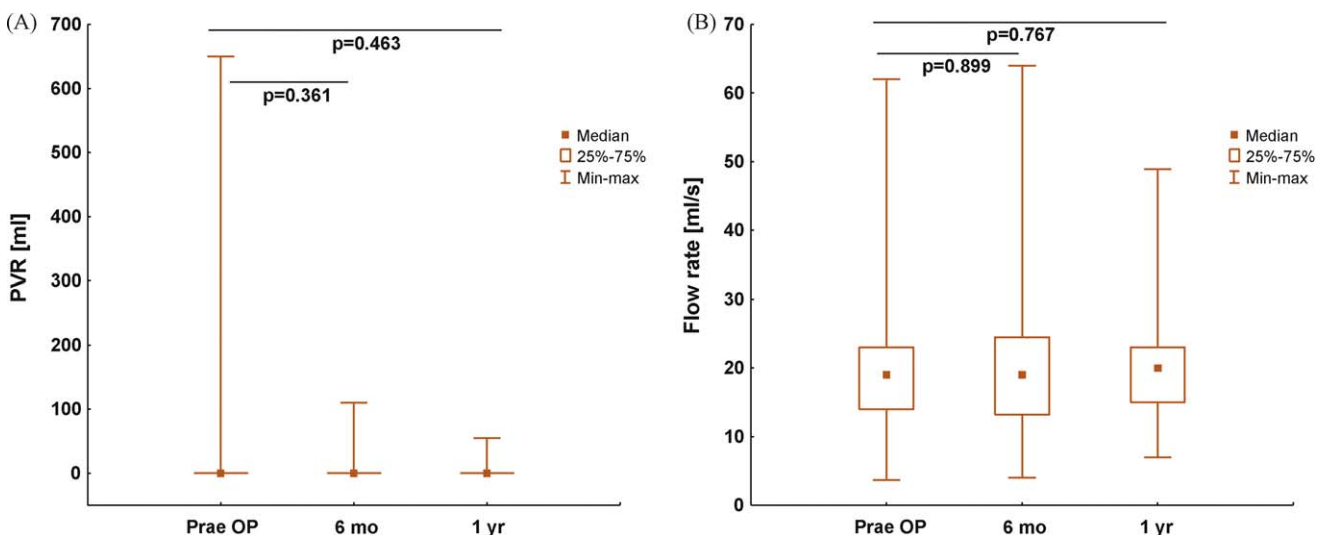


Fig. 2 – Comparison of (A) residual urine and (B) flow rate preoperatively (Prae OP), after 6 months, and after 1 year. PVR = postvoid residual.

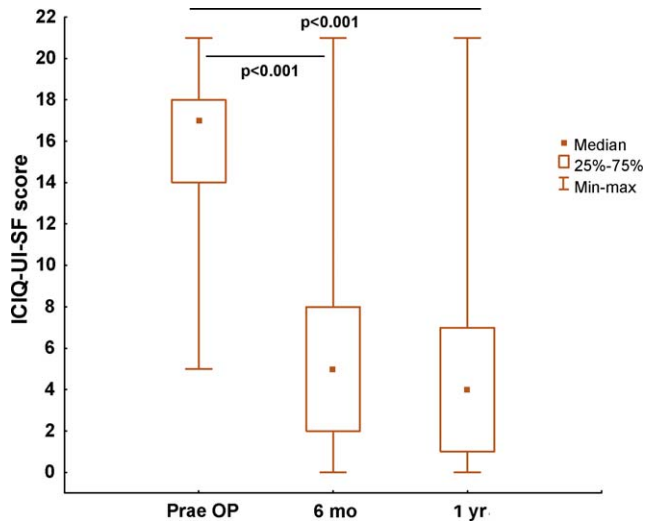


Fig. 3 – Comparison of Incontinence Questionnaire–Urinary Incontinence Short Form (ICIQ-UI SF) score preoperatively (Prae OP), after 6 months, and after 1 year.

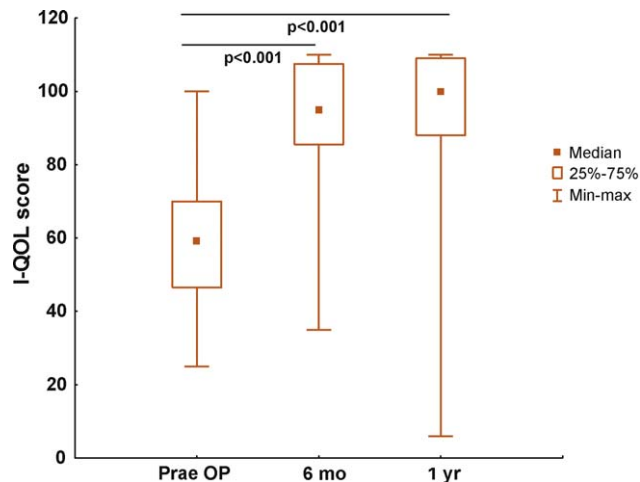


Fig. 4 – Comparison of Incontinence Quality of Life Scale (I-QOL) score preoperatively (Prae OP), after 6 months, and after 1 year.

affecting the mobility of the sphincter region and the posterior urethra (eg, radiotherapy, stem cells, bulking agents) are expected to have a negative impact on the retrourethral transobturator sling outcome; however, no statistically significant difference was seen in this study. This can be attributed to the small number of patients with prior radiotherapy, stem cells, or bulking agents but also to the fact that the retrourethral transobturator sling was implanted only in patients with a detectable hypermobility of the sphincter region and good residual sphincter function due to the absence of intrinsic sphincter deficiency. Further research is needed to evaluate to what extent prior treatment or patient selection may influence the outcome.

The complication rate for the retrourethral transobturator sling in our series seems acceptable: No severe intraoperative complications were seen except for one misplaced sling, which was explanted later on. After this incident, an intraoperative urethroscopy was performed

routinely after sling placement to avoid further inappropriate placements. Additionally, no severe postoperative complications were seen, and the explantation rate was comparably low with 0.8% after 1 yr [4,6,9,10,20]. The main postoperative complication was AUR in 12.9% of the patients. In all cases, the urinary retention resolved within 2–10 wk without further treatment. A spasm of the external sphincter was detected in all of these patients by performing flexible urethroscopy postoperatively. No anatomic obstruction of the urethra could be seen in the urethroscopy. Thus, we hypothesized functional rather than obstructive retention as the most likely cause for AUR. Correlation with the type of anaesthesia is unlikely because the catheter was removed 3 d after surgery. AUR due to spinal anaesthesia is unlikely.

In the present study, significant improvement of QoL was seen after implantation of the retrourethral transobturator sling. Successfully treated men regained more and more physical activity and a normal social life.

5. Conclusions

The functional retrourethral transobturator sling offers an effective, safe, and minimally invasive treatment option for male patients with SUI after RP. Pretreatments like radiotherapy, stem cell therapy, and bulking agents seemed to have limited influence on the outcome. In contrast to other treatment options, retrourethral transobturator sling represents a functional approach, exerting its effect on the posterior urethra.

Author contributions: Ricarda M. Bauer had full access to all the data in the study and takes responsibility for the integrity of the data and the accuracy of the data analysis.

Study concept and design: Bauer, Stief, Gozzi.

Acquisition of data: Bauer, Mayer, Soljanik, Gratzke.

Analysis and interpretation of data: Bauer, Gozzi, Buchner, Bastian, Stief.

Drafting of the manuscript: Bauer.

Critical revision of the manuscript for important intellectual content: Gozzi, Bastian, Stief.

Statistical analysis: Buchner.

Obtaining funding: None.

Administrative, technical, or material support: Mayer, Soljanik, Gratzke, Buchner.

Supervision: Stief, Gozzi.

Other (specify): None.

Financial disclosures: I certify that all conflicts of interest, including specific financial interests and relationships and affiliations relevant to the subject matter or materials discussed in the manuscript (eg, employment/affiliation, grants or funding, consultancies, honoraria, stock ownership or options, expert testimony, royalties, or patents filed, received, or pending), are the following: Christian Gozzi holds the intellectual property as a co-inventor of the procedure. Christian Gozzi declares consultancy work, lectures, and participation in clinical trials for AMS. Ricarda M. Bauer declares lectures for AMS. All authors declare that no funding or other agreement has limited their ability to fairly complete and publish this data and that they had full control of the primary data.

Funding/Support and role of the sponsor: None.

References

- [1] Bauer RM, Bastian PJ, Gozzi C, Stief CG. Postprostatectomy incontinence: all about diagnosis and management. *Eur Urol* 2009;55:322–33.
- [2] Graefen M, Walz J, Huland H. Open retropubic nerve-sparing radical prostatectomy. *Eur Urol* 2006;49:38–48.
- [3] Walsh PC, Partin AW, Epstein JI. Cancer control and quality of life following anatomical radical retropubic prostatectomy: results at 10 years. *J Urol* 1994;152:1831–6.
- [4] Fassi-Fehri H, Badet L, Cherrass A, et al. Efficacy of the InVance™ male sling in men with stress urinary incontinence. *Eur Urol* 2007;51:498–503.
- [5] Hubner WA, Schlarp OM. Treatment of incontinence after prostatectomy using a new minimally invasive device: adjustable continence therapy. *BJU Int* 2005;96:587–94.
- [6] Hübner WA, Schlarp OM. Adjustable continence therapy (ProACT™): evolution of the surgical technique and comparison of the original 50 patients with the most recent 50 patients at a single centre. *Eur Urol* 2007;52:680–6.
- [7] Kumar A, Litt ER, Ballert KN, Nitti VW. Artificial urinary sphincter versus male sling for post-prostatectomy incontinence—what do patients choose? *J Urol* 2009;181:1231–5.
- [8] Rajpurkar AD, Onur R, Singla A. Patient satisfaction and clinical efficacy of the new perineal bone-anchored male sling. *Eur Urol* 2005;47:237–42, discussion 242.
- [9] Romano SV, Metrebian SE, Vaz F, et al. An adjustable male sling for treating urinary incontinence after prostatectomy: a phase III multicentre trial. *BJU Int* 2006;97:533–9.
- [10] Sousa-Escandón A, Cabrera J, Mantovani F, et al. Adjustable suburethral sling (Male Remeex System) in the treatment of male stress urinary incontinence: a multicentric European study. *Eur Urol* 2007;52:1473–80.
- [11] Romano SV, Metrebian SE, Vaz F, et al. Long-term results of a phase III multicentre trial of the adjustable male sling for treating urinary incontinence after prostatectomy: minimum 3 years [in Spanish]. *Actas Urol Esp* 2009;33:309–14.
- [12] Schroeder A, Abrams P, Andersson KE, et al. Guidelines on urinary incontinence. Arnhem, Netherlands: European Association of Urology; 2009. p. 28–34.
- [13] Rehder P, Gozzi C. Transobturator sling suspension for male urinary incontinence including post-radical prostatectomy. *Eur Urol* 2007;52:860–7.
- [14] Gozzi C, Becker AJ, Bauer R, Bastian PJ. Early results of transobturator sling suspension for male urinary incontinence following radical prostatectomy. *Eur Urol* 2008;54:960–1.
- [15] Avery K, Donovan J, Peters TJ, Shaw C, Gotoh M, Abrams P. ICIQ: a brief and robust measure for evaluating the symptoms and impact of urinary incontinence. *Neurourol Urodyn* 2004;23:322–30.
- [16] Wagner TH, Patrick DL, Bavendam TG, Martin ML, Buesching DP. Quality of life of persons with urinary incontinence: development of a new measure. *Urology* 1996;47:67–71, discussion 72.
- [17] Campos-Fernandes JL, Timsit MO, Paparel P, et al. REMEEEX: a possible treatment option in selected cases of sphincter incompetence [in French]. *Prog Urol* 2006;16:184–91.
- [18] De Leval J, Waltregny D. The inside-out trans-obturator sling: a novel surgical technique for the treatment of male urinary incontinence. *Eur Urol* 2008;54:1051–65.
- [19] Giberti C, Gallo F, Schenone M, Cortese P, Ninotta G. The bone anchor suburethral synthetic sling for iatrogenic male incontinence: critical evaluation at a mean 3-year followup. *J Urol* 2009;181:2204–8.
- [20] Guimaraes M, Oliveira R, Pinto R, et al. Intermediate-term results, up to 4 years, of a bone-anchored male perineal sling for treating male stress urinary incontinence after prostate surgery. *BJU Int* 2009;103:500–4.



eusp
European Urological
Scholarship Programme

The EUSP offers EAU members the following programmes:

- **Scholarship - 1 year for research**
- **Clinical Fellowship - 6 weeks to 3 months**
- **Short Term Visit - 2 to 3 weeks**
- **Visiting Professor**

Application for the various EUSP programmes can be submitted online.
Please visit www.uroweb.org or go directly to <http://www.uroweb.org/professional-resources>