


## ORIGINAL ARTICLE

## Immunodeficiencies

# Lung disease in STAT3 hyper-IgE syndrome requires intense therapy

Carolin Kröner<sup>1,2</sup>  | Jens Neumann<sup>3</sup> | Julia Ley-Zaporozhan<sup>4</sup> | Beate Hagl<sup>1,5</sup> | Iris Meixner<sup>1</sup> | Benedikt D. Spielberger<sup>1,5</sup> | Gregor Dücker<sup>6</sup> | Bernd H. Belohradsky<sup>1</sup> | Tim Niehues<sup>6</sup> | Michael Borte<sup>7</sup> | Joseph Rosenecker<sup>1</sup> | Matthias Kappler<sup>1</sup> | Susanne Nährig<sup>8</sup> | Simone Reu<sup>3</sup> | Matthias Griese<sup>1,2</sup> | Ellen D. Renner<sup>1,5,9</sup>

<sup>1</sup>Department of Pediatrics, Dr. von Hauner Children's Hospital, Ludwig Maximilian University, Munich, Germany

<sup>2</sup>German Center for Lung research (DZL), Munich, Germany

<sup>3</sup>Institute of Pathology, Faculty of Medicine, Ludwig Maximilian University, Munich, Germany

<sup>4</sup>Department of Radiology, Ludwig Maximilian University, Munich, Germany

<sup>5</sup>Environmental Medicine, UNIKA-T, Technical University of Munich and Helmholtz Zentrum Munich, Munich/Augsburg, Germany

<sup>6</sup>HELIOS Children's Hospital, Krefeld, Germany

<sup>7</sup>Children's Hospital, St. Georg Klinikum, Leipzig, Germany

<sup>8</sup>Medizinische Klinik und Poliklinik, Ludwig Maximilian University, Munich, Germany

<sup>9</sup>Hochgebirgsklinik and Christine Kühne-Center for Allergy Research and Education (CK-Care), Davos, Switzerland

**Correspondence**

Ellen Renner, Environmental Medicine, UNIKA-T, Technical University of Munich and Helmholtz Zentrum München, Munich, Germany.  
Email: Ellen.Renner@tum.de

**Funding information**

This work was supported by grants of the Wilhelm-Sander Foundation (2013.015.2), the German Research Foundation (DFG RE2799/6-1), the Fritz-Bender Foundation (to EDR) and DFG-970/8-1, chILD-EU (FP7, No. 305653) and the German Center for Lung Research (DZL) (to MG).

**Abstract**

**Background:** Pulmonary complications are responsible for high morbidity and mortality rates in patients with the rare immunodeficiency disorder STAT3 hyper-IgE syndrome (STAT3-HIES). The aim of this study was to expand knowledge about lung disease in STAT3-HIES.

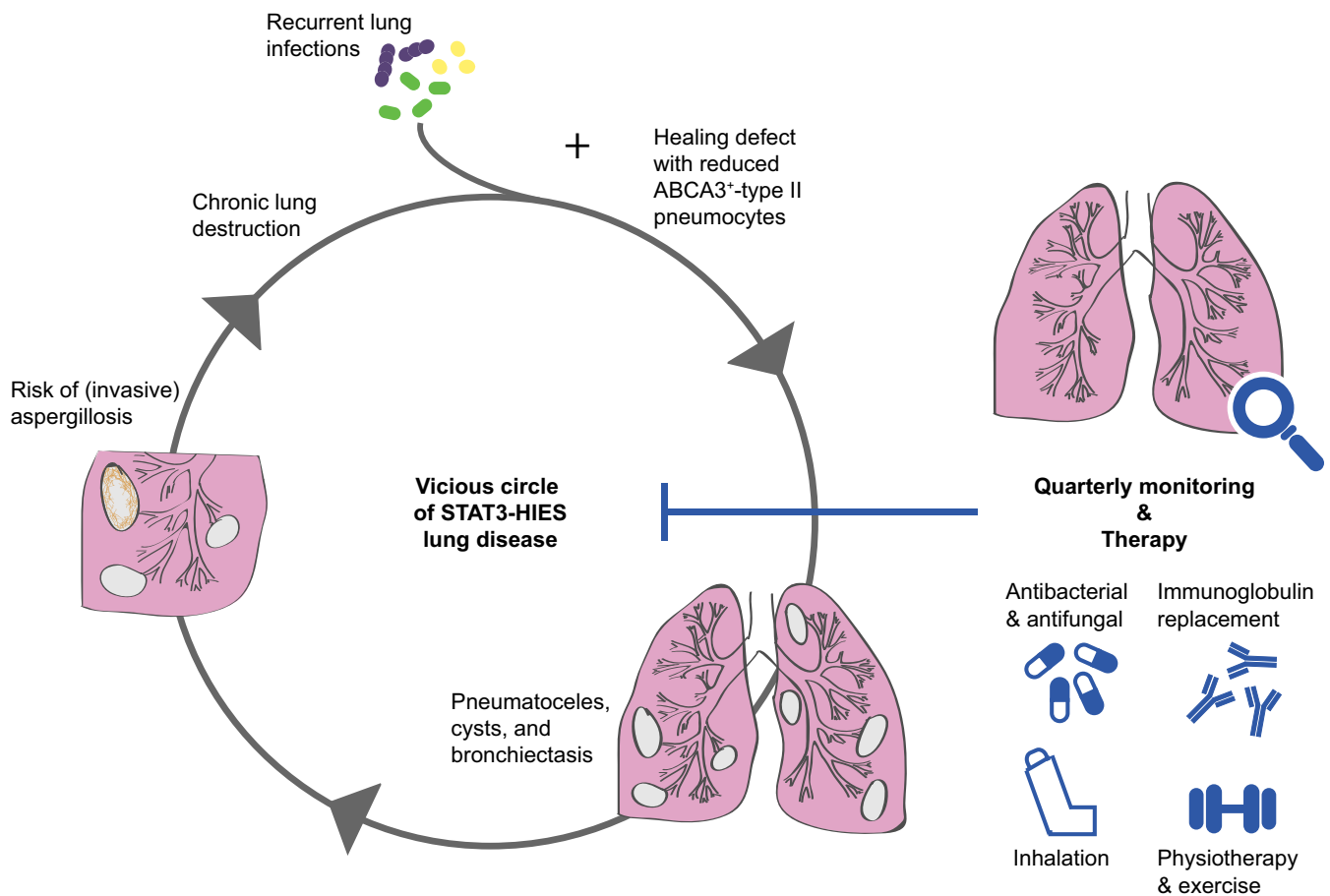
**Methods:** The course of pulmonary disease, radiological and histopathological interrelations, therapeutic management, and the outcome of 14 STAT3-HIES patients were assessed.

**Results:** The patients' quality of life was compromised most by pulmonary disease. All 14 patients showed first signs of lung disease at a median onset of 1.5 years of age. Lung function revealed a mixed obstructive-restrictive impairment with reduced FEV1 and FVC in 75% of the patients. The severity of lung function impairment was associated with *Aspergillus fumigatus* infection and prior lung surgery. Severe lung tissue damage, with reduced numbers of ATP-binding cassette sub-family A member 3 (ABCA3) positive type II pneumocytes, was observed in the histological assessment of two deceased patients. Imaging studies of all patients above 6 years of age showed severe airway and parenchyma destruction. Lung surgeries frequently led to complications, including fistula formation. Long-term antifungal and antibacterial treatment proved to be beneficial, as were inhalation therapy, chest physiotherapy, and exercise. Regular immunoglobulin replacement therapy tended to stabilize lung function.

**Conclusions:** Due to its severity, pulmonary disease in STAT3-HIES patients requires strict monitoring and intensive therapy.

**KEYWORDS**

ABCA3, bronchiectasis, lung disease, pneumatocele, primary immunodeficiency, STAT3 hyper-IgE syndrome



**GRAPHICAL ABSTRACT**

Pulmonary complications in STAT3-HIES patients account for significant morbidity and mortality; patients are endangered by severe postinfectious pulmonary tissue damage including extensive pneumatocele or cyst formation. Strict monitoring and intensive acute and long-term therapy is required including antimicrobial treatment, immunoglobulin replacement therapy (IGRT), inhalation therapy, and chest physiotherapy. Regular IGRT stabilized lung function. Preliminary data hint towards a healing defect associated with reduced ABCA3 expression in type 2 pneumocytes due to STAT3 malfunctioning.

**1 | INTRODUCTION**

Pulmonary complications are responsible for high morbidity and mortality rates in patients with STAT3 hyper-IgE syndrome (STAT3-HIES),<sup>1-4</sup> a primary immunodeficiency disorder characterized by eczema, recurrent bacterial and fungal infections of the skin and lungs, eosinophilia, and elevated serum IgE levels. STAT3-HIES is caused by heterozygous dominant-negative mutations in the *signal transducer and activator of transcription 3 (STAT3)* gene.<sup>5-8</sup> Associated symptoms include a characteristic facial appearance, retained primary teeth, joint hyperextensibility, scoliosis, and minimal trauma fractures.

Recurrent pneumonia, frequently caused by *Staphylococcus aureus* (*S aureus*), *Streptococcus pneumoniae* (*S pneumoniae*), and *Haemophilus influenzae* (*H influenzae*), destroys pulmonary tissue and leads to the formation of abscesses, empyemas, or pneumatoceles and to chronic suppurative lung disease with consecutive bronchiectasis.<sup>3</sup> Lung tissue destruction is likely caused by impaired tissue

repair mechanisms, since mouse models with selective respiratory epithelial STAT3 deficiency show STAT3-dependent repair of bronchiolar and alveolar epithelium.<sup>9</sup> STAT3 is known to regulate the expression of surfactant protein B<sup>10</sup> and to maintain surfactant homeostasis during lung injury<sup>11</sup> through an interleukin 6 (IL-6)-regulated expression of ATP-binding cassette subfamily A member 3 (ABCA3) in type II pneumocytes.<sup>12</sup> ABCA3 belongs to the ABC transporter family<sup>13</sup> and is predominantly expressed in the lamellar bodies of type II pneumocytes, where it is critical for surfactant synthesis and processing.<sup>14,15</sup> The exact interaction of STAT3 and ABCA3 remains, however, unclear. Therapeutic options in STAT3-HIES, such as hematopoietic stem cell transplant (HSCT), are of uncertain benefit.<sup>16</sup> In particular, pulmonary complications such as pneumatoceles and bronchiectasis have been shown to persist after HSCT, though the frequency of pulmonary infections may be reduced.<sup>17</sup> Lung transplantation has been reported for a single patient, who died due to pulmonary posttransplant *Aspergillus fumigatus* (*A fumigatus*) infection and transplant vasculopathy.

For the management of more frequent lung diseases, such as cystic fibrosis (CF) or non-CF bronchiectasis, marked by repeated infections and chronic inflammation,<sup>18-20</sup> regularly updated therapy guidelines have significantly improved patients' outcome and quality of life.<sup>18-20</sup> Despite the severity of lung disease in STAT3-HIES, few studies exist on its follow-up and therapeutic management.<sup>2-4</sup>

The aim of this study was to assess clinical details of STAT3-HIES lung disease, the potential role of ABCA3 in disease pathogenesis, and the effectiveness of pulmonary treatment.

## 2 | MATERIALS AND METHODS

Fourteen STAT3-HIES patients (8 male, 6 female; median 22.4 years of age; range 6-50) carrying a heterozygous *STAT3* mutation and followed at or together with the Children's Hospital of the Ludwig-Maximilians University (LMU) were included. All patients except patient #8 were reported previously.<sup>5,21,22</sup> The median NIH score, defining HIES above 40 points,<sup>23</sup> was 62 points (range 37-86) (Table 1).

The LMU review board (#381-13) approved the study; all patients and/or their legal guardians provided written informed consent.

Clinical records of each patient were reviewed. Patients and their guardians completed a questionnaire with respect to pulmonary symptoms, interventions, and the effect of treatment (no improvement or improvement of cough, sputum, dyspnoea, upper respiratory infections, pneumonias or other). All patients rated the negative impact of HIES symptoms on a scale from 1 to 10 (1: "not severe", 10: "very severe"). Chest X-rays (CXRs) (48 for 11 patients) and CTs (28 for 10 patients) were evaluated in each lung section (upper, middle, lower lobe, lingula) for the presence of alterations: pleura (pleural thickening or effusion), mediastinum (heart, hilar, or mediastinal lymph node enlargement), lung parenchyma (mosaic attenuation; diffuse or patchy ground-glass opacity; consolidation; linear, reticular, or nodular opacity; honeycombing; cyst; cavity; hyper-inflated secondary lobule; emphysema; air-trapping; septal thickening), and airways (bronchiectasis; traction bronchiectasis/architectural distortion; bronchial wall thickening; tree-in-bud). Lung function tests were performed on 12 patients; a median of 8 investigations per patient was available. Median FEV1 and FVC were calculated per year with respect to the start of immunoglobulin replacement therapy (IGRT) and compared to age-related published values.<sup>24,25</sup>

Formalin-fixed and paraffin-embedded lung samples from two deceased STAT3-HIES patients were analyzed and compared to eight non-neoplastic and not STAT3-HIES affected lung tissues without pathological alterations, randomly selected by the Institute of Pathology, LMU Munich. Immunohistochemistry was performed with primary antibody against ABCA3 protein (Seven Hills Bioreagents, Cincinnati, United States) as previously described.<sup>26</sup> The numbers of ABCA3-positive and total type II pneumocytes were quantified in ten randomly selected alveoli with and without signs of inflammation. The mean values were compared using GraphPad Prism 5.0 (GraphPad Software Inc., San Diego, CA, USA).

## 3 | RESULTS

### 3.1 | Respiratory symptoms

Families graded the pulmonary symptoms as severe (median score: 9 points, range 1-10) in comparison to other HIES symptoms, while the negative impact of overall HIES symptoms was graded as less severe (7 points, range 2-10). Eight of 13 patients reported that lung symptoms were the worst, alone or in combination with skin problems (n = 5), ear (n = 3) and bone (n = 3) problems and the psychological burden (n = 2).

Pulmonary symptoms were present in all 14 patients with a median onset of 1.5 years of age (Table 1). All patients had recurrent otitis media with a median number of episodes of 8 times/year (range 3-8 times/year) and starting at a median of 11 months of age (range 2 weeks-6 years). Thirteen patients had a history of at least one episode of pneumonia, chronic pulmonary symptoms, or radiological signs of progressive lung disease. Patient #3 had no history of pneumonia but suffered from chronic cough. Pneumonia frequency ranged from none to 3 per year per patient. Nine patients needed frequent hospitalization for respiratory exacerbations, and 7 patients required oxygen supplementation. Hemoptysis occurred in 9 patients, in 6 repeatedly. Allergic asthma, triggered by aeroallergens, such as pollen, dust mites, or animal hair, was diagnosed in 3 patients (#9, #10, #12). One patient (#10) used nebulized corticosteroids and salbutamol daily, and two patients salbutamol on demand.

### 3.2 | Lung function

Lung functions showed a mixed obstructive-restrictive impairment in 75% of patients with an overall median FEV1 of 52.1% predicted (range 30.9-106.9) and an overall median FVC of 64.5% predicted (range 35.1-101.8) (Table 1). Lung function impairment was associated with prior lung surgery and *A fumigatus* infection. Normal or slightly impaired FEV1 and FVC values above 80% predicted (median FEV1 89.1% predicted, range 81-106.9; median FVC 90.8% predicted, range 82.6-101.8) were observed in 4 patients (#1, #4, #6, #14), who were *A fumigatus*-negative yet patient #1 and #4 were *P. aeruginosa*-positive. All 4 patients had no prior lung surgery; patient #6 had once an abscess drainage.

All 8 *A fumigatus*-positive patients, of whom 6 were also *P aeruginosa*-positive, had severely impaired FEV1 and FVC with median values below 80% predicted (median FEV1 48.7% predicted, range 30.9-56.0; median FVC 55% predicted, range 35.1-69.9; FVC not available in one patient). Seven of these 8 *A fumigatus*-positive patients had a history of lung tissue loss from surgery; patient #13 had only a history of lung abscess drainage, but she had a severe scoliosis, explaining her lower FEV1 and FVC levels. Eight patients had bronchodilator response tests with salbutamol; median delta FEV1 was in all patients below 15% and thus below bronchial asthma threshold.

Median annual FEV1 and FVC values in the first 3 years prior to IGRT and in the first 8 years after the start of IGRT are shown in

**TABLE 1** Clinical characteristics and applied therapy in 14 patients with STAT3-HIES

Age at follow-up (y)	Sex	First pulmonary symptoms (age [y])	Chronic lung tissue damage in CT	Minimal documented FEV1 (% pred) (age [y])	Hemoptysis (frequency)	<i>P. aeruginosa</i> -positive respiratory specimen	<i>A. fumigatus</i> -positive respiratory specimen	Lung surgery (age [y])	Prophylactic antibiotic therapy (effect*)	Prophylactic antifungal therapy (effect*)	IGRT (since age [y]) (effect*)	Inhalation therapy (effect*)	Physiotherapy (effect*)	CF adapted therapy <sup>b</sup> (effect*)	NIH score <sup>22</sup> at follow-up	Heterozygous STAT3-mutation
1	M	Chronic cough, pneumonia, repeated bronchitis (1)	None	106.9 (6)	No	Yes	No	No	Yes (+)	Yes (+)	Yes (1) (+)	Yes (-)	No	No	51	p.R382W
2	M	Chronic cough, pneumonia (2.5)	None	na	No	No	No	No	No	Yes (+)	Yes (7.5) (+)	Yes (+)	No	No	37	p.R382Q
3	M	Chronic cough (3)	na	na	No	No	No	No	No	No	Yes (8) (+)	Yes (+)	No	No	48	p.R382Q
4	F	Chronic cough, repeated bronchitis, pneumonia (1)	Bronchiectasis, pneumatocele	84.8 (11)	Yes (repeated)	Yes <sup>c</sup>	No	No	Yes (na)	Yes (+)	Yes (12) (+)	Yes (+)	No	Yes (+)	62	p.V637M
5	F	Pneumonia (3.5)	Bronchiectasis, traction bronchiectasis/architectural distortion, caverna, emphysema	29.9 (15)	Yes (repeated)	No	Yes <sup>c</sup>	Pneumectomy (4), lobectomy (5)	Yes (+)	Yes (+)	Yes (16) (-)	Yes (+)	Yes (+)	No	67	p.R382Q
6	M	Repeated bronchitis (1.5)	Bronchiectasis, traction bronchiectasis/architectural distortion, pneumatocele, cysts	64 (16)	Yes (once)	No	No	Abscess drainage (15)	Yes (+)	Yes (-)	Yes (11) (+)	Yes (+)	Yes (+)	No	82	p.R382W
7	M	Chronic cough, pneumonia, dyspnea (0)	Bronchiectasis, traction bronchiectasis/architectural distortion, pneumatocele	26.2 (19)	Yes (repeated)	Yes <sup>c</sup>	Yes <sup>d</sup>	Lobectomy (3)	Yes (+)	Yes (na)	Yes (13) (+)	Yes (+)	Yes (+)	Yes (-)	60	p.R382Q
8	F	Chronic cough, pneumonia (4)	na	50 (21)	Yes (once)	Yes	Yes	Lobectomy (4), bilobectomy (9)	Yes (+)	No	Yes (11) (+)	Yes (+)	Yes (+)	No	44	p.Q469R

(Continues)

TABLE 1 (Continued)

Age at follow-up (y)	Sex	First pulmonary symptoms (age [y])	Chronic lung tissue damage in CT	Minimal documented FEV1 (% pred) (age [y])	Hemoptysis (frequency)	<i>P. aeruginosa</i> -positive respiratory specimen	<i>A. fumigatus</i> -positive respiratory specimen	Lung surgery (age [y])	Prophylactic antibiotic therapy (effect <sup>a</sup> )	Prophylactic antifungal therapy (effect <sup>a</sup> )	IGRT (since age [y]) (effect <sup>a</sup> )	Inhalation therapy (effect <sup>a</sup> )	Physiotherapy (effect <sup>a</sup> )	CF adapted therapy <sup>b</sup> (effect <sup>a</sup> )	NIH score <sup>22</sup> at follow-up	Heterozygous STAT3-mutation
9	F	Chronic cough, repeated bronchitis (0.3)	Bronchiectasis, traction bronchiectasis/architectural distortion, multiple cysts, pleural thickening	22.2 (21)	Yes (once)	Yes <sup>c</sup>	Yes <sup>d</sup>	Decortication, pleurectomy (13.20); pneumectomy (21)	Yes (+)	Yes (na)	Yes (22) (+)	Yes (+)	Yes (+)	Yes (+)	86	p.R382Q
10	F	Pneumonia, dyspnea (4)	Bronchiectasis, traction bronchiectasis/architectural distortion	37 (21)	Yes (repeated)	Yes	Yes	Lobectomy (4)	Yes (+)	Yes (-)	Yes (18) (-)	No	No	No	72	p.V713L
11	M	Na	Bronchiectasis, traction bronchiectasis/architectural distortion, large caverna, cysts, centrilobular emphysema	36 (27)	Yes (repeated)	Yes	Yes <sup>d</sup>	Bilobectomy (24)	Yes (na)	Yes (na)	No	na	na	na	85	p.R382W
12	M	Chronic cough, pneumonia, dyspnea (1.5)	Small bullae, linear opacities (cicatriziation), pleural thickening	32.6 (34)	No	No	Yes <sup>d</sup>	Lobectomy (1.5), abscess drainage/pleurolysis (21), lobectomy(24)	Yes (+)	Yes (+)	No	No	No	Yes (-)	61	p.F348L
13	F	Chronic cough, repeated bronchitis, dyspnea (0)	Traction bronchiectasis/architectural distortion, cysts	39 (36)	Yes (repeated)	Yes	Yes	Abscess drainage (9)	Yes (+)	Yes (+)	Yes (33) (+)	Yes (+)	No	Yes (+)	71	p.R382W
14	M	Pneumonia (6)	Emphysema	81 (50)	No	No	No	No	Yes (na)	Yes (na)	No	No	No	No	53	p.R382W
Summary	Median age 22.4 (6-50)	8M, 6F median age 1.5 (0-6)	10/12	Median minimal FEV1 38 (22.2-106.9)	9/14	8/14	8/14	9/14, median age at first surgery 4 (1.5-24)	12/14	12/14	11/14 (median age at start 12 (1-33))	10/13	5/13	5/13	Median 61.5 (37-86)	

<sup>a</sup>Patient observation.

<sup>b</sup>Every 4-6 wk alternating inhaled and oral antibiotic treatment, for example with nebulized tobramycin and oral ciprofloxacin.

<sup>c</sup>More than 1 year.

<sup>d</sup>Invasive aspergillosis.

+: Positive effect; -: No positive effect.

*A. fumigatus* Aspergillus fumigatus; f, female; FEV1, forced expiratory volume in 1 s; IGRT, immunoglobulin replacement therapy; m, male; na, information not available; NIH, National Institute of Health; *P. aeruginosa*, *Pseudomonas aeruginosa*; pred, predicted.

Figure 1. Within the first 5 years after starting IGRT, median FEV1 increased in 5 of 6 patients under IGRT and remained stable in patient #8, while FVC increased in 4 patients and remained stable in patients #8 and #13. In patient #7, FEV1 and FVC improved continuously within 5 years after starting IGRT, while an acute pulmonary exacerbation led to the current lung function impairment. Two patients (#11, #12) not receiving IGRT had a FEV1 decrease of 21% predicted (#11) and 20% predicted (#12) and a FVC decrease of 27.6% predicted (#11) and 9% predicted (#12) in comparable time frames of 7 and 3.6 years.

### 3.3 | Radiological imaging assessment

CXR and CT assessment revealed severe lung parenchyma and airway destruction in all, except 3 patients (#1, #2, #3) below 6 years of age. Frequent parenchymal and airway alterations are presented in Table 2, Figure 2. Cystic parenchymal abnormalities included cysts, pneumatoceles, and cavities; they arose during infection and often persisted. Extensive emphysema formation was observed in 3 older patients (#12, #11, #14), all smokers (Figure 2). Severe scoliosis and rib fractures were documented in 6 patients each.

### 3.4 | Microbiology assessment

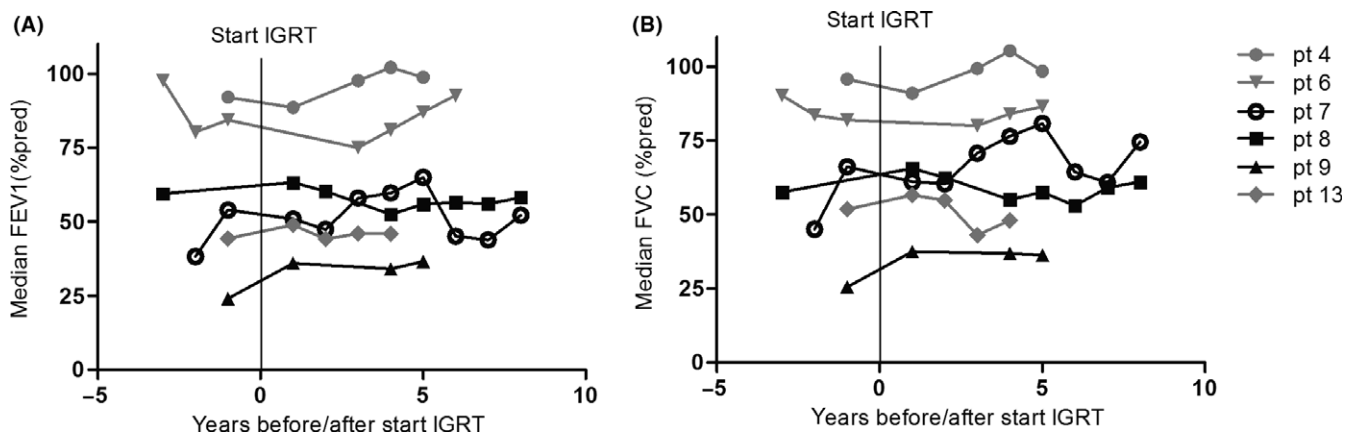
The respiratory tract flora, analyzed by throat swab or sputum, was repeatedly positive for *S aureus*, *H influenzae*, *S pneumoniae*, and *Candida species* in most patients. Less frequently observed were *Serratia liquefaciens*, *Moraxella catharralis*, *Klebsiella oxytoca*, *Chlamydia species*, *Acinetobacter baumannii*, and *Burkholderia cepacia*. Possible oral or environmental contaminants included *Penicillium species*, *Neisseria sicca*, and *Candida species*. *P aeruginosa* was identified in the respiratory specimen of more than half (57%) of the patients at least once;

median at first detection was 12.2 years of age (range 4-25) (Table 1). Three patients (#4, #7, #9) were *P aeruginosa*-positive for more than 1 year. Eradication therapy was unsuccessful in one patient (#4) and intermittently successful in 2 patients (#7, #9). *P aeruginosa* status showed no correlation with lung function or radiological alterations.

*Methicillin-resistant S aureus (MRSA)* was identified in respiratory specimen of 3 patients (#1, #10, #13) and was successfully eradicated, defined by lack of detection 2 years after eradication therapy. ESBL-producing *Escherichia coli* was isolated once from respiratory specimen of 2 patients (#7, #13).

One patient (#8) had a viral pneumonia at 10 years of age, several days after a systemic varicella infection. She developed a necrotizing pneumonia with an acute respiratory distress syndrome, requiring mechanical ventilation. Tracheal secretions were PCR-positive for *Varicella zoster virus* and *Cytomegalovirus*. The patient stabilized after 20 days of intensive mechanical ventilation, a right-sided pneumectomy, and antibiotic and antiviral therapy, the patient stabilized.

Respiratory specimens were positive for *A fumigatus* in 8 patients at a median of 17.8 years of age at first detection (range 10-33.6). All 8 patients had bronchiectasis, traction bronchiectasis, cysts, bullae, pneumatocele, or lung cavities. Five patients had invasive aspergillosis according to the EORTC/MSG definitions,<sup>27</sup> and two patients died because of *Aspergillus*-associated complications at 16.8 and 28.8 years of age. Autopsy results showed that the causes of death were an *A fumigatus* pneumonia and a severe bacterial bronchopneumonia in patient #5 and a respiratory insufficiency after lung hemorrhage originating from a 10-cm *A fumigatus*-positive, thick-walled cavity in patient #11 (Figure 2). Predominant histological findings in both patients were bronchiectasis, fibrosis, granulomas, several aspergillomas, cavities and signs of acute and chronic infection.



**FIGURE 1** Course of forced expiratory volume in 1 s (FEV1, % predicted) (A) and forced vital capacity (FVC, % predicted) (B) in relation to the start of regular immunoglobulin replacement therapy (IGRT) of 6 STAT3-HIES patients. Patients with (black colored lines) and without (gray colored lines) a history of significant lung surgery and associated loss of lung tissue are depicted, demonstrating the overall lower FEV1 and FVC values after lung surgery. All available median FEV1 and FVC values per year are shown in the years 1-3 prior to IGRT and in the years 1-8 after start of IGRT. Median FEV1 values increased in 5 out of 6 patients under IGRT in the first 5 y after starting IGRT and remain relatively stable in one patient (#8), while FVC values increased in 4 out of 6 patients and remained relatively stable in patients #8 and 13)

**TABLE 2** Radiological findings in chest CTs of 10 STAT3-HIES patients

CT finding	Number of patients positive for finding
Pleural space	
Enlarged hilar lymph nodes	3
Parenchyma	
Mosaic attenuation	4
Ground-glass opacity (patchy)	9
Consolidation	7
Linear opacity	3
Emphysema	3
Cyst	6
Pneumatocele	7
Caverna	3
Airways	
Bronchial wall thickening	8
Bronchiectasis	7
Traction bronchiectasis/architectural distortion	7
Tree-in-bud	4

Chronic inflammation was dominant with lymphocytes and plasma cells; in some areas, inflammation was active with few neutrophil granulocytes. Mild desquamative inflammatory reaction with alveolar macrophages was also present.

### 3.5 | Immunohistochemical assessment of lung tissue

Epithelial ABCA3 expression and the abundance of type II pneumocytes in lung tissue of 2 deceased STAT3-HIES patients were compared with randomly selected human lung tissue. Numbers of pneumocytes per alveolus in STAT3-HIES were comparable to control lung tissue, as was their increase in inflamed lung tissue. There were, however, less ABCA3-positive type II pneumocytes in STAT3-HIES patients compared to controls, both in areas with and without inflammation (Figure 3).

### 3.6 | Lung surgery

Lung surgeries were performed in referring hospitals in 9 patients at a median of 4 years of age at first surgery (range 1.5–24) (Table 1). Five patients received up to 3 interventions. Procedures included lobectomy (n = 7), abscess drainage (n = 5), pleurolysis (n = 2), pleurectomy (n = 1), decortication (n = 1), wedge resection due to pneumatocele (n = 2), and unilateral pneumectomy (n = 2). Postoperative complications were frequent and severe, including postoperative, prolonged pneumonia due to *S aureus* and *Candida albicans* (n = 1), acute *A fumigatus* infection (n = 2), persistent empyema (n = 3), and bronchopleural fistula (n = 4). The latter two complications required up to 4 postoperative revisions in 2 patients (#9, #12).

Figure 4 illustrates the benefit of intensive intravenous antibiotic and antifungal treatment of an acute infection as opposed to surgical intervention. Patient #7 presented at 12.4 years of age with acute fever, cough and breathing-dependent pain. CXR showed the acute infection of a large pneumatocele in the left upper lobe, including fluid mirror and callus formation in the adjacent pleural fissure. After 10 weeks of intensive intravenous therapy with teicoplanin, ceftazidime, tobramycin, fosfomycin, metronidazole, and ambisome, he recovered clinically, the air-fluid level disappeared, and FEV1 increased from 50.9% predicted at admission to 62.6% predicted.

### 3.7 | Therapy

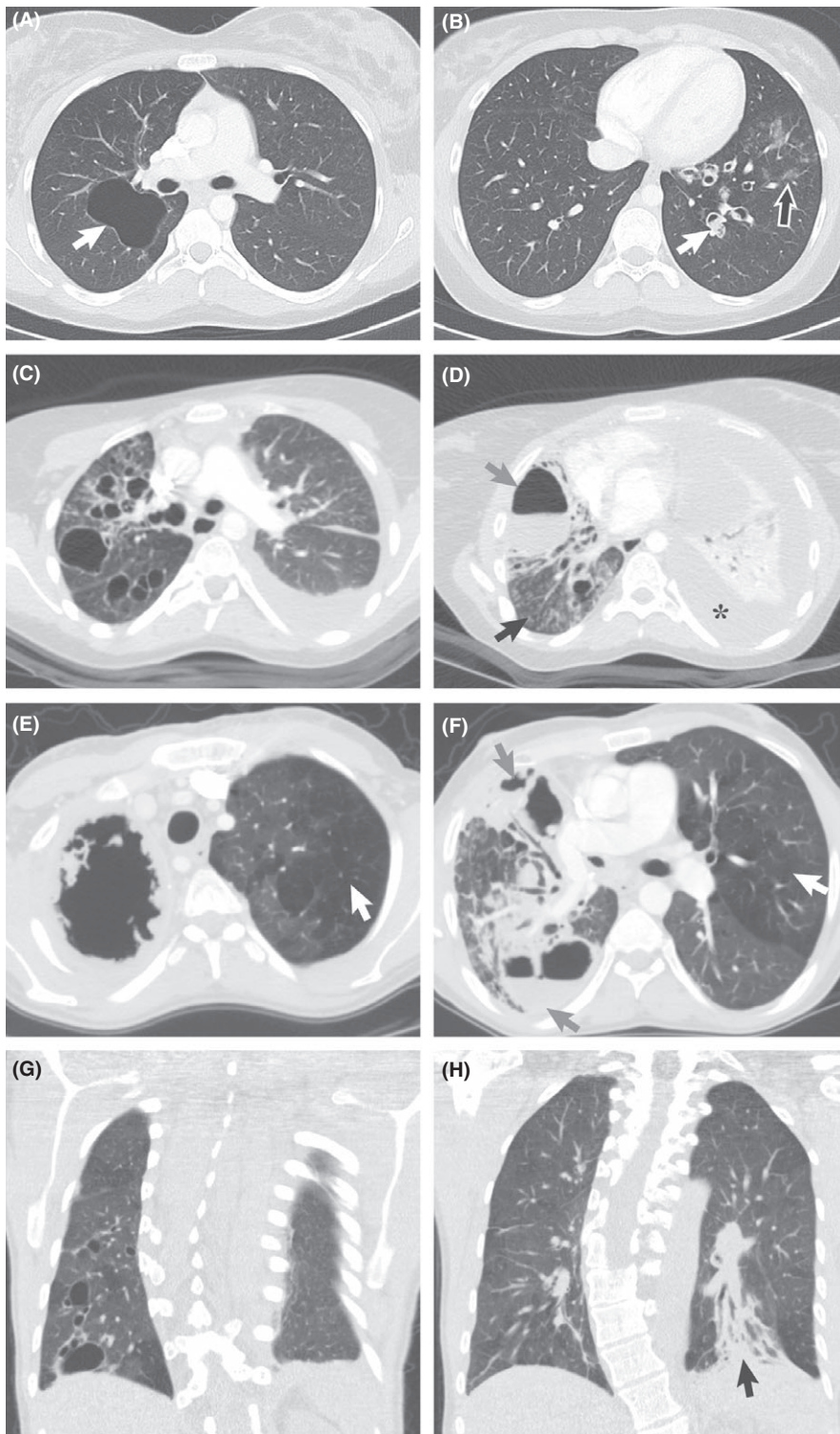
Continuous antibiotic therapy was started in response to repeated respiratory tract and other (eg, skin) infections at a median of 4 years of age (range 2–17) in 12 patients, mainly with trimethoprim/sulfamethoxazole (n = 11) and first or second grade cephalosporins (n = 9). Two patients (#2, #3) discontinued regular antibiotic therapy. Nine patients reported a positive effect on pulmonary symptoms, leading to less cough, sputum, dyspnea, and less respiratory infections (Table 1).

Five patients (#4, #5, #8, #9, #13) received repeated elective intravenous antibiotic therapy depending on microbiologic sputum analysis, as a combination therapy with for example, tobramycin and ceftazidime, over 2–3 weeks, either upon general pulmonary deterioration or on a regular basis every 6–12 months. Five patients (#4, #7, #9, #12, #13) received a combination therapy with oral antibiotics (eg, ciprofloxacin) and nebulized antibiotics (eg, colistin), alternating in 4–8 week intervals, starting at a median of 12 years of age (range 8–33). More than 60% of the patients reported a positive effect resulting in less cough, less sputum, and an improved general physical condition. Repeated respiratory exacerbations were treated effectively with fluoroquinolones.

Antifungal treatment with itraconazole was initiated due to mucocutaneous candidiasis in 9 patients at a median of 3.7 years of age (range 2–17). Six patients received posaconazole or itraconazole, and one patient nebulized amphotericin B after the detection of *A fumigatus* in respiratory specimen. A beneficial effect was noted by 6 patients.

Regular monthly intravenous or weekly subcutaneous IGRT (recommended dosage: 0.4 g per kg of body weight per month) was started in 11 patients at a median of 12 years of age (range 1–33), in response to worsening respiratory symptoms or a worsening general condition. In addition to the positive effect of IGRT on lung function, patients reported fewer upper respiratory infections and bronchitis (72%), fewer pneumonia (55%), less sputum (45%), improved physical condition (18%), less fatigue (1%), and an improved skin condition (27%).

Nine of 10 patients reported that inhalation with hypertonic or isotonic sodium chloride lead to less cough, less sputum, less dyspnoea, better expectoration, and better physical condition. Other inhaled agents included salbutamol (patients #5, #7, #9, #10) and ipratropium (patient #7).



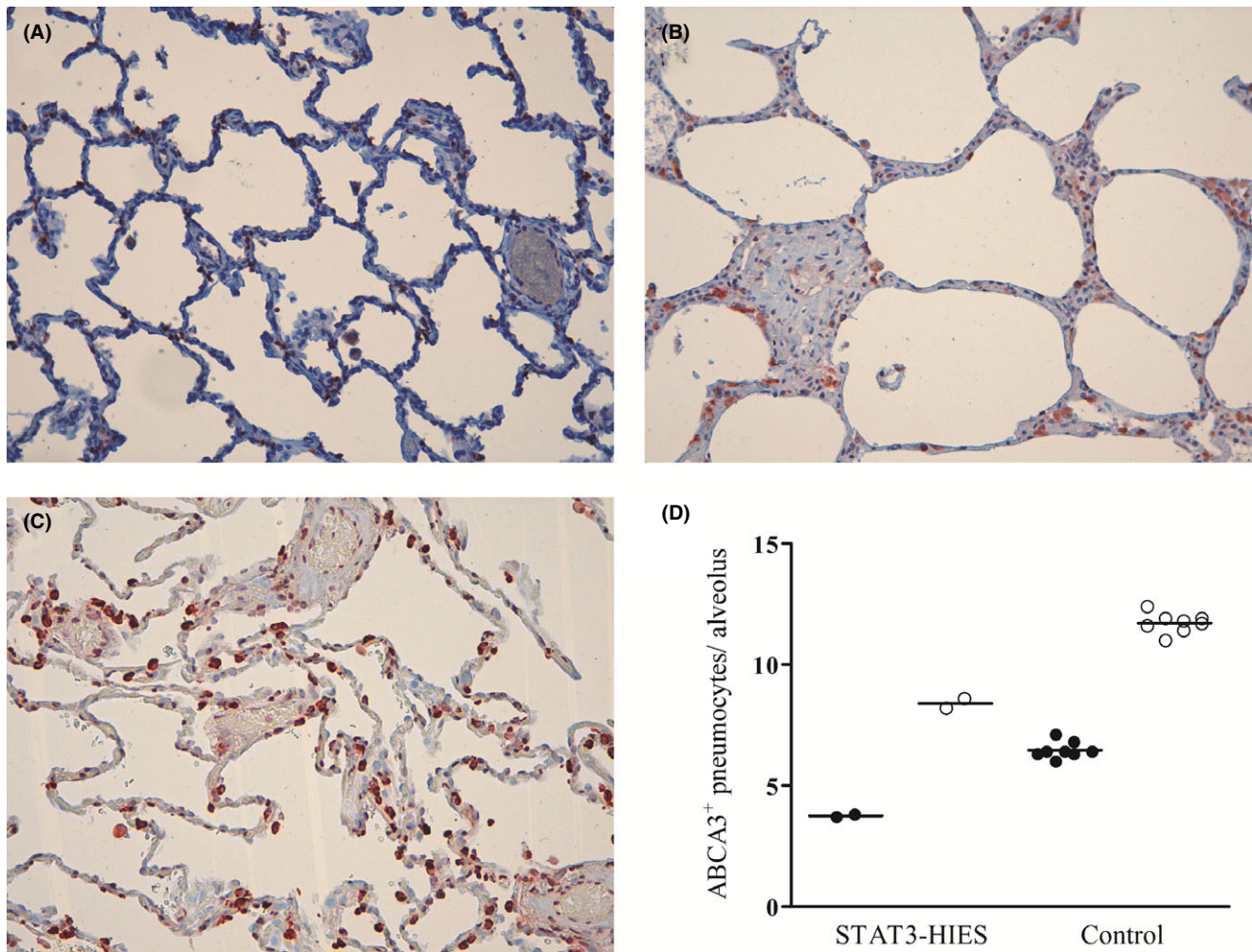
**FIGURE 2** Selection of chest computed tomographies (CTs) of characteristic lung damage of parenchyma and airways in STAT3-HIES patients show: A large pneumatocele (2A, white arrow) and mucus-filled bronchiectasis (2B, white arrow), bronchial wall thickening, and ground-glass opacities (2B, black arrow) in patient #4 at 15 y of age; multiple cysts (2C), a large air-fluid cavity (2D, gray arrow), traction bronchiectasis with wall thickening and extensive tree-in-bud (2D, black arrow) on the right side, and a large pleural effusion (2D, asterisks) with compression atelectasis in the left lower lobe in patient #9 at 20.2 y of age; right upper lobe destruction with a large thick-walled air-filled cavity (2E) and multiple smaller cavities, partly with air-fluid level (2F, gray arrow), consolidation areas and bronchiectasis in the right lung as well as emphysema (white arrow) in the left lung of patient #11 at 28.3 y of age. Severe scoliosis, multiple cysts on the right side (2G), and chronic consolidation with traction bronchiectasis are present in the left lower lobe (2H, arrow) in patient #13 at 33.8 y of age

Three patients (#4, #6, #13) received aerosolized recombinant human deoxyribonuclease (rhDNase), an enzyme breaking down DNA strands in airway secretions to reduce viscoelasticity<sup>28</sup> and frequently used in CF. Patient #4 experienced first hemoptysis a few weeks after starting rhDNase at 11.3 years of age, and patient #13 reported an improvement of dyspnea at 33 years of age, however, stopped therapy shortly after due to habitual

hemoptysis. The now 17-year-old patient #6 is on rhDNase therapy since 6.8 years of age, reporting that rhDNase yielded the best effect of all applied therapies, and having had only one episode of hemoptysis.

Five patients performed guided chest physiotherapy (up to 2 times per week) and 8 patients a workout program (up to 5 times per week); all reported a positive effect on pulmonary symptoms.





**FIGURE 3** Immunohistochemical analysis of ABCA3 protein in lung tissue of two patients with STAT3-HIES. Reduced amount of ABCA3-positive type II pneumocytes after staining with primary antibody against ABCA3 protein (200-fold magnification) in uninfamed lung tissue of patient # 5 (A) and #11 (B) compared to eight non-neoplastic and not STAT3-HIES affected lung tissues randomly selected from the archive of the Institute of Pathology, LMU Munich, one healthy control is shown (C). Number of ABCA3-positive type II pneumocytes in 10 randomly selected alveoli of lung tissue from patients #5 and #11, in lung areas without (black dots) and with inflammation (white dots) compared to eight controls (D)

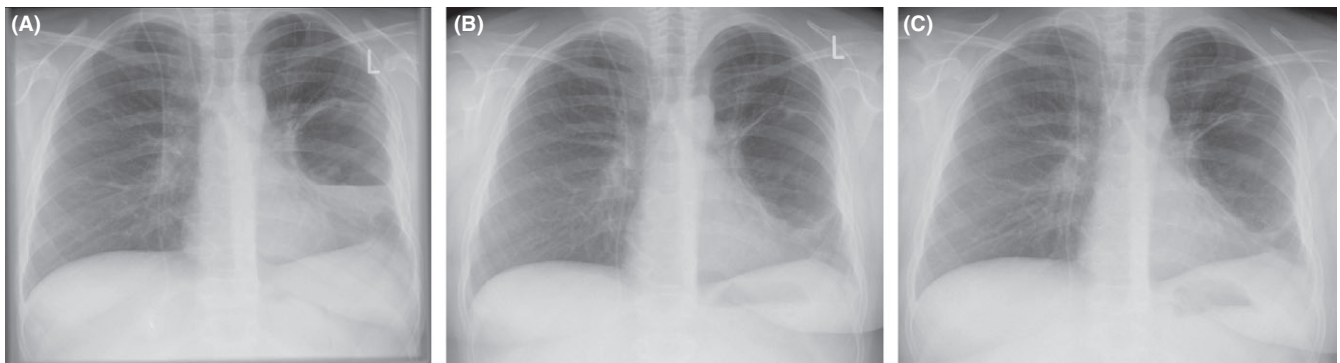#### 4 | DISCUSSION

The relevance of pulmonary involvement in STAT3-HIES is undisputed.<sup>1,3,4</sup> Pulmonary symptoms are a heavy burden for patients with STAT3-HIES. All but one of our patients had a history of pneumonia, confirming the reported pneumonia prevalence of 90%–100%.<sup>4,22,29</sup> In similar frequency as reported previously, recurrent pneumonia sequentially led to severe lung tissue destruction with abscess, pneumatocele, cyst, and cavity formation and to bronchiectasis (with and without traction).<sup>4,29,30</sup> Bronchiectasis was present in this cohort above 9 years of age.

Lung sequels in STAT3-HIES are not yet well understood but are thought to be triggered by several factors, such as impaired clearance of infection, tenacious mucus-enhancing bronchiectasis development, delayed diagnosis of pneumonia due to diminished signs of systemic inflammation with lack of fever and of inflammatory markers, and impaired tissue repair mechanisms.<sup>3</sup> The lack of

inflammatory response and clearance of infection is explained by the dominant negative effect of mutated STAT3 on the inflammatory IL-6 pathway.<sup>3,7,21,31</sup> Furthermore, STAT3 regulates the expression of surfactant protein B<sup>10</sup> and maintains surfactant homeostasis after lung injury<sup>11</sup> through IL-6-regulated expression of ABCA3 in type II pneumocytes.<sup>12</sup> Therefore, we assessed ABCA3 expression in human lung tissue and for the first time identified reduced ABCA3 expression in STAT3-HIES patients, suggesting that impaired surfactant homeostasis via ABCA3 expression may be involved in pathophysiology of lung disease in STAT3-HIES.

Hematopoietic stem cell transplant, a treatment of choice in several primary immunodeficiencies, is of questionable benefit in STAT3-HIES,<sup>16,17</sup> likely due to extra-hematopoietic alterations, and its inability to correct existing pulmonary complications. Lung surgery does not cure the underlying STAT3 defect, has a high rate of complications, reduces the total amount of functional lung tissue, and thus has a negative effect on the long-term outcome.<sup>2</sup>



**FIGURE 4** Clinical course in a patient with conservative treatment of an acute pulmonary exacerbation. CXR (A) of patient #7 at 12.4 y of age after admission due to acute pulmonary exacerbation with acute fever, cough, and breathing-dependent pain showing a thick-walled (preexisting) pneumatocele with air-fluid level and thickening of the pleural surface on the left side consistent with superinfection. The patient was treated over a period of 10 wk with intensive multiple antibiotic and antifungal i.v. therapy; CXR follow-up showed 6 wk after admission (B) an improved air-fluid level and 4 wk later (C) a thin-walled pneumatocele without fluid content

Instead, infection prevention and limitation are highly recommended. In primary immunodeficiencies, weekly subcutaneous or monthly intravenous IGRT (recommended dosage: 0.4 g per kg of body weight per month) is a standard therapy to replace missing specific immunoglobulin G (IgG) and reduce infection. Despite the fact that STAT3-HIES patients show normal serum levels of total IgG, they lack *S aureus*-specific IgG<sup>32</sup> and show variable antibody responses to vaccines, for example, against *S pneumoniae*,<sup>33</sup> which likely explains the observed reduction in the incidence of bacterial pneumonias by 33% in patients receiving IGRT compared to patients without IGRT.<sup>4</sup> Here, we find a stabilization of lung function under IGRT with positive effects on respiratory infections and the physical condition.

We recommend continuous oral *S aureus* effective antibiotic therapy in all patients, including intense intravenous antibiotic treatment of respiratory exacerbations, regular intravenous antibiotic therapy in selected patients with a high frequency of pulmonary exacerbations as well as the use of fluoroquinolones in case of exacerbation.

In CF, chronic *P aeruginosa* infection is associated with a worse disease outcome<sup>34,35</sup> and early eradication therapy, followed by long-term nebulized antibiotics is recommended.<sup>18,20</sup> Despite limited data,<sup>1,4</sup> *P aeruginosa* eradication regimens may also benefit STAT3-HIES patients.

A significant mortality rate is associated with *A fumigatus* in STAT3-HIES, which was also responsible for the death of two patients in this group. Fungal treatment in therapeutic dosages for all STAT3-HIES patients with *Aspergillus* colonization is suggested, especially if pneumatoceles, cysts, or bronchiectasis are present.<sup>3,4</sup> Posaconazole is preferred despite the expense because of better bioavailability and its good long-term risk profile.<sup>36</sup>

Regular inhalation therapy in chronic suppurative lung diseases, such as CF, increases surface liquid and improves mucociliary clearance. In STAT3-HIES, mucociliary clearance is potentially also impaired, due to an altered differentiation of basal cells into ciliated cells.<sup>3,9</sup> Our patients reported that inhalation therapy with (hypertonic) saline, chest physiotherapy, airway clearance techniques, and

workout programs was beneficial. Aerosolized rhDNAse in CF is known to reduce the progression of lung disease<sup>28</sup> but should be halted if there is pulmonary hemorrhage. Detrimental effects on lung function and frequency of pulmonary exacerbations have been shown in other diseases, such as idiopathic bronchiectasis,<sup>37</sup> and from our point of view, the risk of rhDNAse treatment in STAT3-HIES—with frequent lung hemorrhage due to dilated and fragile bronchial arteries<sup>3</sup>—outweighs the potential benefits. Accordingly, nebulized corticosteroids<sup>38</sup> are not recommended due to the immunodeficiency in STAT3-HIES as they are associated with an increased risk for infections.

Our observations are based on a cohort of patients with a rare disease; therefore, the overall level of evidence is low. Prospective observations are needed, yet difficult to carry out due to the rareness of the condition and the need for individualized treatment. We and others<sup>1,3,4</sup> observed lung disease in STAT3-HIES as not self-limiting and demanding aggressive treatment. We felt comfortable transferring knowledge generated in CF to STAT3-HIES patients. Our report highlights the importance of monitoring pulmonary symptoms in STAT3-HIES patients very closely, in order to detect pulmonary infections before tissue is severely damaged. We suggest a regular, quarterly monitoring scheme, as proposed for CF by the European Cystic Fibrosis Society Standards of Care,<sup>18</sup> including clinical examinations, airway cultures, lung function tests, annual CXR, and, depending on clinical need, lung-CT. Treatment should include long-term antibiotic and antifungal treatment, regular IGRT, daily inhalation therapy, chest physiotherapy, and physical activity to prevent and to eliminate infections.

#### ACKNOWLEDGMENTS

We thank all patients and their families for their participation and the primary care physicians, technicians, nurses, and Julie Sawalle-Belohradsky for their support, and Stephen Starck (TUM) for language advice. Data included in this publication are part of a medical thesis at the School of Medicine, LMU Munich (IM).

## AUTHOR CONTRIBUTIONS

CK, JN, BH, IM, MG, and EDR performed data acquisition and analysis; CK, JLZ, BDS, GD, TN, MB, JR, MK, SN, MG, and EDR analyzed clinical data; CK, JLZ, and MG analyzed radiological imaging; CK, JN, and SR performed pathological investigation and analysis; MG and EDR supervised research; CK, BH, and EDR created the graphical abstract; CK, MG, and EDR designed the research and were the principal writers of the manuscript. All authors reviewed the manuscript and contributed in writing.

## CONFLICT OF INTEREST

The authors declare that they have no conflicts of interest.

## ORCID

Carolin Kröner  <https://orcid.org/0000-0002-9474-3870>

## REFERENCES

- Freeman AF, Kleiner DE, Nadiminti H, et al. Causes of death in hyper-IgE syndrome. *J Allergy Clin Immunol.* 2007;119(5):1234-1240.
- Freeman AF, Renner ED, Henderson C, et al. Lung parenchyma surgery in autosomal dominant hyper-IgE syndrome. *J Clin Immunol.* 2013;33(5):896-902.
- Freeman AF, Olivier KN. Hyper-IgE syndromes and the lung. *Clin Chest Med.* 2016;37(3):557-567.
- Chandesris MO, Melki I, Natividad A, et al. Autosomal dominant STAT3 deficiency and hyper-IgE syndrome: molecular, cellular, and clinical features from a French national survey. *Medicine (Baltimore).* 2012;91(4):e1-e19.
- Hagl B, Heinz V, Schlesinger A, et al. Key findings to expedite the diagnosis of hyper-IgE syndromes in infants and young children. *Pediatr Allergy Immunol.* 2016;27(2):177-184.
- Holland SM, DeLeo FR, Elloumi HZ, et al. STAT3 mutations in the hyper-IgE syndrome. *N Engl J Med.* 2007;357(16):1608-1619.
- Minegishi Y, Saito M, Tsuchiya S, et al. Dominant-negative mutations in the DNA-binding domain of STAT3 cause hyper-IgE syndrome. *Nature.* 2007;448(7157):1058-1062.
- Renner ED, Torgerson TR, Rylaarsdam S, et al. STAT3 mutation in the original patient with Job's syndrome. *N Engl J Med.* 2007;357(16):1667-1668.
- Tadokoro T, Wang Y, Barak LS, Bai Y, Randell SH, Hogan BL. IL-6/STAT3 promotes regeneration of airway ciliated cells from basal stem cells. *Proc Natl Acad Sci USA.* 2014;111(35):E3641-E3649.
- Yan C, Naltner A, Martin M, Naltner M, Fangman JM, Gurel O. Transcriptional stimulation of the surfactant protein B gene by STAT3 in respiratory epithelial cells. *J Biol Chem.* 2002;277(13):10967-10972.
- Hokuto I, Ikegami M, Yoshida M, et al. Stat-3 is required for pulmonary homeostasis during hyperoxia. *J Clin Invest.* 2004;113(1):28-37.
- Matsuzaki Y, Besnard V, Clark JC, et al. STAT3 regulates ABCA3 expression and influences lamellar body formation in alveolar type II cells. *Am J Respir Cell Mol Biol.* 2008;38(5):551-558.
- Dean M, Hamon Y, Chimini G. The human ATP-binding cassette (ABC) transporter superfamily. *J Lipid Res.* 2001;42(7):1007-1017.
- Yamano G, Funahashi H, Kawanami O, et al. ABCA3 is a lamellar body membrane protein in human lung alveolar type II cells. *FEBS Lett.* 2001;508(2):221-225.
- Ban N, Matsumura Y, Sakai H, et al. ABCA3 as a lipid transporter in pulmonary surfactant biogenesis. *J Biol Chem.* 2007;282(13):9628-9634.
- Patel NC, Gallagher JL, Torgerson TR, Gilman AL. Successful haploidentical donor hematopoietic stem cell transplant and restoration of STAT3 function in an adolescent with autosomal dominant hyper-IgE syndrome. *J Clin Immunol.* 2015;35(5):479-485.
- Yanagimachi M, Ohya T, Yokosuka T, et al. The potential and limits of hematopoietic stem cell transplantation for the treatment of autosomal dominant hyper-IgE syndrome. *J Clin Immunol.* 2016;36(5):511-516.
- Smyth AR, Bell SC, Bojcin S, et al. European cystic fibrosis society standards of care: best practice guidelines. *J Cyst Fibros.* 2014;13(Suppl 1):S23-S42.
- Pasteur MC, Bilton D, Hill AT, British Thoracic Society Non CFBGG. British Thoracic Society guideline for non-CF bronchiectasis. *Thorax.* 2010;65(7):577.
- Mogayzel PJ Jr., Naureckas ET, Robinson KA, et al. Cystic fibrosis pulmonary guidelines. Chronic medications for maintenance of lung health. *Am J Respir Crit Care Med.* 2013;187(7):680-689.
- Renner ED, Rylaarsdam S, Anover-Sombke S, et al. Novel signal transducer and activator of transcription 3 (STAT3) mutations, reduced T(H)17 cell numbers, and variably defective STAT3 phosphorylation in hyper-IgE syndrome. *J Allergy Clin Immunol.* 2008;122(1):181-187.
- Schimke LF, Sawalle-Belohradsky J, Roesler J, et al. Diagnostic approach to the hyper-IgE syndromes: immunologic and clinical key findings to differentiate hyper-IgE syndromes from atopic dermatitis. *J Allergy Clin Immunol.* 2010;126(3):611-617 e611.
- Grimbacher B, Schaffer AA, Holland SM, et al. Genetic linkage of hyper-IgE syndrome to chromosome 4. *Am J Hum Genet.* 1999;65(3):735-744.
- Zapletal A, Samanek M. [Flow resistance of airways and pulmonary flow resistance in children and juveniles. Normal values and their significance for the evaluation of airway obstruction]. *Cesk Pediatr.* 1977;32(9):513-522.
- Quanjer PH, Tammeling GJ, Cotes JE, Pedersen OF, Peslin R, Yernault JC. Lung volumes and forced ventilatory flows. Report Working Party Standardization of Lung Function Tests, European Community for Steel and Coal. Official Statement of the European Respiratory Society. *Eur Respir J Suppl.* 1993;16:5-40.
- Kroner C, Wittmann T, Reu S, et al. Lung disease caused by ABCA3 mutations. *Thorax.* 2016;72:213-220.
- De Pauw B, Walsh TJ, Donnelly JP, et al. Revised definitions of invasive fungal disease from the European Organization for Research and Treatment of Cancer/Invasive Fungal Infections Cooperative Group and the National Institute of Allergy and Infectious Diseases Mycoses Study Group (EORTC/MSG) Consensus Group. *Clin Infect Dis.* 2008;46(12):1813-1821.
- Fuchs HJ, Borowitz DS, Christiansen DH, et al. Effect of aerosolized recombinant human DNase on exacerbations of respiratory symptoms and on pulmonary function in patients with cystic fibrosis. The Pulmozyme Study Group. *N Engl J Med.* 1994;331(10):637-642.
- Woellner C, Gertz EM, Schaffer AA, et al. Mutations in STAT3 and diagnostic guidelines for hyper-IgE syndrome. *J Allergy Clin Immunol.* 2010;125(2):424-432 e428.
- Flinn AM, Cant A, Leahy TR, Butler KM, Gennery AR. Autosomal dominant hyper IgE syndrome—treatment strategies and clinical outcomes. *J Clin Immunol.* 2016;36(2):107-109.
- Meyer-Bahlburg A, Renner ED, Rylaarsdam S, et al. Heterozygous signal transducer and activator of transcription 3 mutations in hyper-IgE syndrome result in altered B-cell maturation. *J Allergy Clin Immunol.* 2012;129(2):559-562, 562 e551-552.

32. Stentzel S, Hagl B, Felicitas A, et al. Reduced IgG response to *Staphylococcus aureus* in STAT3 hyper-IgE syndrome. *Clin Infect Dis*. 2017;64:1279-1282.
33. Sheerin KA, Buckley RH. Antibody responses to protein, polysaccharide, and phi X174 antigens in the hyperimmunoglobulinemia E (hyper-IgE) syndrome. *J Allergy Clin Immunol*. 1991;87(4):803-811.
34. Li Z, Kosorok MR, Farrell PM, et al. Longitudinal development of mucoid *Pseudomonas aeruginosa* infection and lung disease progression in children with cystic fibrosis. *JAMA*. 2005;293(5):581-588.
35. Nixon GM, Armstrong DS, Carzino R, et al. Clinical outcome after early *Pseudomonas aeruginosa* infection in cystic fibrosis. *J Pediatr*. 2001;138(5):699-704.
36. Raad II, Graybill JR, Bustamante AB, et al. Safety of long-term oral posaconazole use in the treatment of refractory invasive fungal infections. *Clin Infect Dis*. 2006;42(12):1726-1734.
37. O'Donnell AE, Barker AF, Ilowite JS, Fick RB. Treatment of idiopathic bronchiectasis with aerosolized recombinant human DNase I. rhDNase Study Group. *Chest*. 1998;113(5):1329-1334.
38. Sabroe I, Postma D, Heijink I, Dockrell DH. The yin and the yang of immunosuppression with inhaled corticosteroids. *Thorax* 2013;68(12):1085-1087.

**How to cite this article:** Kröner C, Neumann J, Ley-Zaporozhan J, et al. Lung disease in STAT3 hyper-IgE syndrome requires intense therapy. *Allergy*. 2019;00:1–12. <https://doi.org/10.1111/all.13753>