

ORIGINAL ARTICLE

Lung disease caused by *ABCA3* mutations

Carolin Kröner,¹ Thomas Wittmann,¹ Simone Reu,² Veronika Teusch,³ Mathias Klemme,⁴ Daniela Rauch,¹ Meike Hengst,¹ Matthias Kappler,¹ Nazan Cobanoglu,⁵ Tugba Sismanlar,⁶ Ayse T Aslan,⁶ Ilaria Campo,⁷ Marijke Proesmans,⁸ Thomas Schaible,⁹ Susanne Terheggen-Lagro,¹⁰ Nicolas Regamey,¹¹ Ernst Eber,¹² Jürgen Seidenberg,¹³ Nicolaus Schwerk,¹⁴ Charalampos Aslanidis,¹⁵ Peter Lohse,¹⁶ Frank Brasch,¹⁷ Ralf Zarbock,¹ Matthias Griese¹

► Additional material is published online only. To view please visit the journal online (<http://dx.doi.org/10.1136/thoraxjnl-2016-208649>).

For numbered affiliations see end of article.

Correspondence to

Professor Dr Matthias Griese, Department of Pediatric Pneumology, Dr. von Hauner Children's Hospital, LMU, German Center for Lung research (DZL), Lindwurmstraße 4, Munich 80337, Germany; matthias.griese@med.uni-muenchen.de

Received 29 March 2016

Revised 7 June 2016

Accepted 12 July 2016

Published Online First

11 August 2016

ABSTRACT

Background Knowledge about the clinical spectrum of lung disease caused by variations in the ATP binding cassette subfamily A member 3 (*ABCA3*) gene is limited. Here we describe genotype-phenotype correlations in a European cohort.

Methods We retrospectively analysed baseline and outcome characteristics of 40 patients with two disease-causing *ABCA3* mutations collected between 2001 and 2015.

Results Of 22 homozygous (15 male) and 18 compound heterozygous patients (3 male), 37 presented with neonatal respiratory distress syndrome as term babies. At follow-up, two major phenotypes are documented: patients with (1) early lethal mutations subdivided into (1a) dying within the first 6 months or (1b) before the age of 5 years, and (2) patients with prolonged survival into childhood, adolescence or adulthood. Patients with null/null mutations predicting complete *ABCA3* deficiency died within the 1st weeks to months of life, while those with null/other or other/other mutations had a more variable presentation and outcome. Treatment with exogenous surfactant, systemic steroids, hydroxychloroquine and whole lung lavages had apparent but many times transient effects in individual subjects.

Conclusions Overall long-term (>5 years) survival of subjects with two disease-causing *ABCA3* mutations was <20%. Response to therapies needs to be ascertained in randomised controlled trials.

INTRODUCTION

The ATP-binding cassette subfamily A member 3 (*ABCA3*) protein is a 1704 amino acid protein, belonging to the ABC transporter family,¹ encoded by a single gene with 33 exons located on chromosome 16.^{2,3} *ABCA3* is predominantly expressed in lung tissue,⁴ localised to the membranes of the lamellar bodies of alveolar type II cells, where it is critical for pulmonary surfactant synthesis and processing.⁵ *ABCA3* mutations have been associated with lethal neonatal respiratory distress,^{6–8} paediatric and adult interstitial lung disease,^{8–12} and surfactant metabolism dysfunction.^{13,14} In a recent study, genotype-phenotype correlation with respect to outcome was analysed in a cohort of 185

Key messages**What is the key question?**

- What is the phenotype of patients with two disease-causing mutations in the ATP-binding cassette subfamily A member 3 (*ABCA3*) surfactant lipid transporter gene and how does it correlate to genotype?

What is the bottom line?

- In a cohort of 40 subjects three phenotypes were differentiated, patients with null/null mutations died before the age of 6 months, long-term (>5 years) survival in this cohort was <20% and response to treatment was uncertain.

Why read on?

- Explore in-depth clinical, biochemical, radiological and histological characteristics of patients with pulmonary disease caused by *ABCA3* mutations for a better understanding of this orphan disease.

patients.⁷ With respect to clinical details, several case reports^{6,15–20} and one case series with nine patients are available,²¹ larger studies reporting clinical phenotype details with association to genotype are lacking.

In this study, we broaden the clinical knowledge about this patient group by presenting genetic, biochemical, clinical, radiological and histological findings in a cohort of 40 patients from Europe.

METHODS**Patients**

All children and adults identified in the programme for rare lung diseases of the Kids Lung Register (KLR) between 1 January 2001 and 30 June 2015 with homozygous or compound heterozygous mutations in the *ABCA3* gene were included in this study (figure 1). Previously published patients were included with additional information and/or for completion of the cohort (see online supplementary tables S1 and S2). The patients'



To cite: Kröner C, Wittmann T, Reu S, et al. *Thorax* 2017;**72**:213–220.

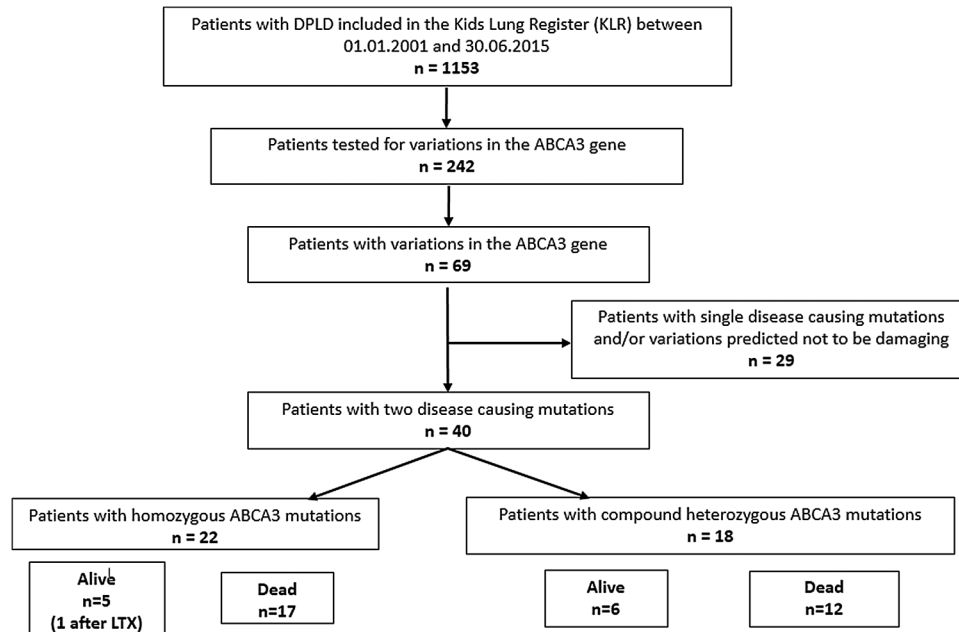


Figure 1 Flow chart of patients included in the study. DPLD, diffuse parenchymal lung disease.

status at last follow-up was compared with the initial presentation and was categorised as dead, sick-worse (the patient had more severe symptoms), sick-same (the symptoms were of similar severity) or sick-better (the patient had milder symptoms and/or less therapy). The patients' response to therapies was analysed from the records and classified in comparison to before the therapy was started: no improvement (therapy did not yield any positive effect), moderate improvement (therapy yielded some positive effect, eg, milder mechanical ventilation, less oxygen needed and/or effect was only transient) and good improvement (therapy yielded a clear positive effect, eg, weaning from mechanical ventilation possible).

Genetic analysis

ABCA3 was analysed using Sanger sequencing (primers are indicated in online supplementary table S3). Variations were grouped according to Wambach *et al.*⁷ missense mutations, insertions and deletions were classified as 'other' mutations, whereas frameshift mutations, nonsense mutations or deletion of an entire exon were classified as 'null' mutations.

Structure-function analysis of previously undescribed ABCA3 mutations

The predicted effect of ABCA3 mutations on protein function was calculated using PROVEAN,²² SIFT²³ and PolyPhen2.²⁴

Total protein and surfactant protein B and C concentration in bronchoalveolar lavage fluid

Surfactant protein B (SP-B) and surfactant protein C (SP-C) were determined in bronchoalveolar lavage fluid (BALF), obtained prior to exogenous surfactant application, using quantitative western blotting.^{25 26}

Lung biopsy, histopathology, electron microscopy and immunohistochemistry

All available lung biopsies were collected as paraffin blocks or slides and evaluated by a pathologist specialised in pulmonary diseases (SR). Histology was scored by severity (0=none, 1=discrete, 2=moderate, 3=strong).²⁷ When material was not

available, we used histopathological categorisation and result of electron microscopy in the records.

Immunohistochemical staining for ABCA3 was performed in all 12 available slides. After pretreatment with Target Unmasking Fluid (Panpath, Amsterdam, the Netherlands) at 90°C, primary antibody against ABCA3 protein (Seven Hills Bioreagents, Cincinnati, USA) was used for 60 min at room temperature, diluted 1:8000. Primary antibody was detected by Vectastain ABC-Kit Elite Universal (Vector Laboratories, Burlingame, USA) and AEC+ chromogen (Dako, Santa Clara, USA), counterstained with haematoxylin Gill's formula (Vector Laboratories). Microscopic pictures were taken with a Leica DM4000 (Leica, Wetzlar, Germany). Slides were blinded and scored semiquantitatively with respect to ABCA3 staining pattern (0=no staining, 1=diffuse staining, 2=ring-like structures stained), ABCA3 aggregates (0=no aggregates, 1=small aggregates, 2=big aggregates) and intensity of ABCA3 staining (0=no staining, 1=weak staining, 2=moderate staining, 3=strong staining). Scoring was analysed using Fisher's exact test. As controls we used tumour-free lung tissue from children (n=10, median age 9.3 years (2.3–17.5)), who received biopsy for diagnosis of pulmonary nodules associated with oncological diseases (nephroblastoma (n=6), hepatoblastoma (n=1), osteosarcoma (n=2), nerve sheath tumour (n=1)).

Radiological studies

Radiological studies were scored by a paediatric radiologist (VT) according to the criteria of Fleischner Society.²⁸ CT scans and chest X-rays (CXR) were rated in three sections on the left and right sides: apex to carina, carina to lower pulmonary vein and lower pulmonary vein to diaphragm. The incidence of hilar lymphadenopathy, ground glass opacity, cysts, bronchial wall thickening, bronchiectasis/peripheral bronchial dilatation, reticular pattern, nodular pattern, lobe retraction and consolidation was evaluated for each lung section on both, CXR and CT scans. CT scans were in addition assessed for honeycombing, crazy paving and paraseptal emphysema, CXRs for hyperinflation. Each item was scored as 0=none, 1=discrete, 2=diffuse or 3=very strong. Mean values were calculated per patient for each feature.

Statistical analysis

Prism 6 for windows was used for statistical analysis. The Fisher's exact test was used to test the hypothesis that frequencies of ABCA3 staining pattern, ABCA3 aggregates and the intensity of ABCA3 staining were different between normal subjects and patients carrying ABCA3 mutations. Survival curves were compared by two methods: the log-rank test and the Gehan-Breslow-Wilcoxon test, which gives more weight at early time points.

Ethics

All parents or guardians of the children gave informed consent; adolescents assented. Retrospective data analysis was approved by the institutional review board (EK 026-06), and collection of data and material was performed under the project FP7-305653-chILD-EU (EK 111-13).

RESULTS

Between 1 January 2001 and 30 June 2015, 1153 patients with diffuse parenchymal lung disease (DPLD) were registered in the KLR. The DNA of 242 of these patients was sequenced for ABCA3 mutations. Sixty-nine patients had at least one variation in the ABCA3 gene. Twenty-nine patients with only a single disease-causing mutation and/or patients with variations predicted not to be damaging were excluded from the study. Of 40 patients with two disease-causing ABCA3 mutations, 22 patients were homozygous and 18 patients compound heterozygous (figure 1).

Clinical course of patients with homozygous mutations

Twenty-two patients (15 male) carried homozygous ABCA3 mutations (see online supplementary table S1). The parents of 17/18 patients were consanguine. The parents of 14/17 patients were Caucasian, 2/17 African, 1/17 Indian. In 8/10 families with sufficient information one or two prior abortions, and/or family members who died from lung disease between 0 month and 11 months of age were recorded (see online supplementary table S4). Immediately or within a few hours after birth, 19/22 patients presented as mature newborns with severe respiratory distress, requiring mechanical ventilation. Three of the patients described in detail by Campo *et al*¹⁰ developed symptoms late during disease course. Hundred per cent of patients with null/null mutations died at a median age of 0.11 years, while 62% of patients with other/other mutations died at a median age of 0.25 years (see online supplementary table S1, figure 2). Two homozygous patients underwent lung transplantation (LTX), one is still alive at 3.3 years. Therapy with exogenous surfactant was applied to 17 patients, with no effect in 7 patients, and moderate but transient improvement in 9 patients. Therapy with systemic steroids was administered to 21 patients, with no effect in 14 patients, moderate improvement in 5 patients and good improvement in 1 patient. Therapy with hydroxychloroquine was tried in 10 patients, showing no effect in 5 patients, moderate but transient improvement in 3 patients and good improvement in 1 patient. Azithromycin application showed moderate improvement in one patient, and had no effect in two patients (see online supplementary table S1).

Clinical course of patients with compound heterozygous mutations

Eighteen patients had compound heterozygous ABCA3 mutations, 15 were female (see online supplementary table S2). The majority of the parents were heterozygous, not consanguine.

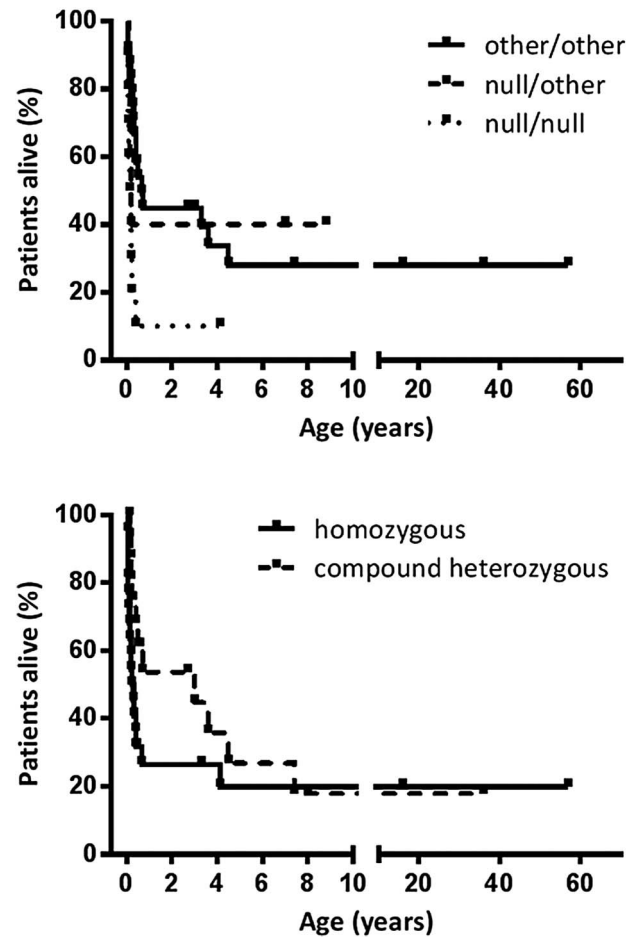


Figure 2 Kaplan-Meier curve of the survival of all patients with null/null and other/other or null/other mutations in the ATP-binding cassette subfamily A member 3 (ABCA3) gene (upper part) and same patients sorted according to homozygous (consanguinity likely) or compound heterozygous mutational status. Survival curves were compared by two methods: the log-rank test (upper panel $p=0.0148$; lower panel $p=0.1629$) and the Gehan-Breslow-Wilcoxon test, which gives more weight at early time points (upper panel $p=0.0307$; lower panel $p=0.0041$).

Sixteen of 17 families were Caucasian, 1/17 African/Asian. Family history is summarised in online supplementary table S5. Age at presentation was more variable in patients with compound heterozygous ABCA3 mutations compared with patients with homozygous mutations. Thirteen patients presented with neonatal respiratory distress syndrome (RDS), three later in childhood and one in adulthood. Outcome in patients with compound heterozygous ABCA3 mutations was also variable: one patient with lung transplantation died, one patient with null/null genotype died at 0.19 years. Sixty per cent of patients with other/other and 64% with null/other mutations died at a median age of 0.4 years and 0.13 years, respectively (table 1, see online supplementary table S2, figure 2). Treatment with surfactant was applied to 14 patients, without effect in 8 patients, and with moderate, but transient improvement in 4 patients. Fourteen patients were treated with systemic steroids, showing no effect in eight of the patients, while three patients displayed moderate improvement, and one good improvement. Treatment with hydroxychloroquine was administered to eight patients, in three patients without response, while two patients responded well, and three moderately (see online see online supplementary table S2).

Table 1 Phenotype groups of patients with ABCA3 mutations

Group	Phenotype (age (years))	n	Percentage of cohort	Pt ID	Mutation	Type of mutations	Presentation (age (years))	Follow-up (age (years))
<i>(1) Early lethal</i>								
(1a)	(Post)neonatal death (<0.5)	25	62.5		(cf online supplementary table S1)	9 null/null 3 null/other 13 other/other	RDS (neonatal)	Dead (median 0.19, 0–0.32)
(1b)	Death early childhood (0.5–5)	5	12.5	4	p.W308R	Other/other	RDS (neonatal)	LTX (1.5, stable 3.3)
				19	p.W308R p.delEx16 p.delEx16	Null/null	RDS (neonatal)	LTX (1.5, dead 4.1)
				24	p.P193S	Other/other	RDS (neonatal)	LTX (0.6, dead 0.7)
				27	p.G1412R	Other/other	Cough, failure to thrive (0.9)	Dead (4.5)
				28	p.R43C p.R208W	Other/other	Cough, failure to thrive, cyanosis (0.5)	Dead (3.6)
					p.P32S p.G1314E	Other/other	Cough, failure to thrive, cyanosis (0.5)	Dead (3.6)
<i>(2) Prolonged survival</i>								
	Prolonged survival (>5)	7	17.5	37	p.E292V p.E765X	Null/other	RDS (neonatal)	Sick-better (7)
				32	p.D953H p.F1077I	Other/other	Hypoxaemia, clubbing, mycoplasma pneumonia (2.2)	Sick-same (7.4)
				35	p.P969S p.D1439Gfs*11	Null/other	6 days RDS (neonatal), discharge day 11	Sick-same (8.8)
				11	p.G964D p.G964D	Other/other	Cough, PAP (2)	Sick-same (16)
				12	p.G964D p.G964D	Other/other	Cough, dyspnoea (52)	Sick-same (57)
				13	p.G964D p.G964D	Other/other	None (52)	Sick-same (57)
				31	p.G964D p.R709W p.I1193M	Other/other	dyspnoea at exercise, PAP (33)	Sick-same (36)
<i>Patients with observation periods too short for definite allocation likely group</i>								
(1a) or higher				9	p.Q1045R p.Q1045R	Other/other	RDS (neonatal)	sick-better (0.46)
(1b) or higher				23	p.R208W c.3863-98C>T	Other/other	Gestational age 32 weeks, RDS (neonatal)	sick-same (2.7)
(1b) or higher				33	p.Y963C p.E292V	Other/other	NA	sick-same (3)

LTX, lung transplantation; NA, not available; PAP, pulmonary alveolar proteinosis; RDS, respiratory distress syndrome.

To expand knowledge on various phenotypes of DPLD induced by compound heterozygous ABCA3 mutations, case reports of five patients with prolonged survival are presented in online supplement A.

Phenotype groups

With respect to follow-up we observed two phenotypes: patients with early lethal mutations, either (1a) dying within the first 6 months or (1b) before the age of 5 years, and patients with prolonged survival (2) into childhood, adolescence or adulthood (table 1). All but one patient with null/null mutations were in group 1a, patients with null/other and other/other mutations were distributed over all groups.

Surfactant proteins in BALF

Surfactant analysis in 12 patients with homozygous ABCA3 mutations showed no mature SP-C, in one patient abundant SP-C processing forms were detected. SP-B was always present in variable levels (see online supplementary tables S6 and S7). In patients harbouring compound heterozygous ABCA3 mutations, only two patients had normal SP-C levels in relation to SP-B, all other patients had reduced SP-C levels.

Histology and imaging

Histopathological findings in 14 homozygous patients and 10 compound heterozygous patients revealed patterns typical for non-specific interstitial pneumonia (NSIP), desquamative interstitial pneumonia (DIP), pulmonary alveolar proteinosis (PAP) (alone or in combination) or chronic pneumonitis of infancy (CPI). Notably, all patients with CPI (four homozygous and one compound heterozygous) died under 6 months of age. In one patient an usual interstitial pneumonia (UIP) pattern was seen. Electron microscopy imaging showed electron-dense bodies typical for ABCA3 deficiency. Interestingly, one patient with homozygous ABCA3 mutation had few well shaped lamellar bodies with membranes arranged in parallel. Type II pneumocyte hyperplasia, alveolar macrophage accumulation and alveolar septal thickening were the predominant features in 12 available slides. Furthermore, mild or moderate interstitial chronic inflammation and alveolar septal inflammation were recorded. Interstitial fibrosis was also frequent, however, not present in all cases, appearing rather with increasing age (tables 2 and 3).

Lung biopsies obtained in 12 of the patients were used for immunohistochemical staining of ABCA3 protein (see online

Table 2 Histology and electron microscopy of patients with homozygous ABCA3 mutations

Patient ID	Mutation	Overall main pattern	Type II** pneumocyte hyperplasia	Alveolar** macrophage accumulation	Interstitial** fibrosis	Alveolar** septal thickening	Electron-dense bodies	Age at biopsy (years)
1	p.P193R	NSIP, PAP, DIP*					Yes	0.1
3***	p.Q215K, p.R288K	NSIP, PAP, DIP*					Yes	0.1
5	p.K1388N	CPI, strong eosinophilia	3	2	2	2	Yes	p.m., 0.2
7	p.E1364K	CPI					ND	0.4
9	p.Q1045R	DIP					ND	0.3
11	p.G964D	Pulmonary fibrosis with an UIP pattern	2	1	3	3	ND	13
12	p.G964D	Areas with NSIP, with interstitial scarring and normal areas					ND	57
14	p.R1561X	CPI	3	3	0	3	ND	0.1
16	p.R1561X	NA					Yes	0.1
17	p.R1561X	NSIP, DIP*	3	3	1	2	ND	p.m., 0.2
19	Del Ex16,fs	CPI					Yes plus few regular lamellar bodies	0.2
20	p.F810Cfs*2	PAP, NSIP*	2	1	1	1	ND	p.m., 0.0
21	delEx22	Severe interstitial fibrosis, CPI					Yes	0.1
22	p. E1626Vfs*16	PAP					ND	p.m., 0.1

*Combined picture of; **severity of indicated finding 0=none, 1=discrete, 2=moderate, 3=strong, severity indicated for available material; ***two homozygous variations. CPI, chronic pneumonitis of infancy; DIP, desquamative interstitial pneumonia; NA, not available; ND, not done; NSIP, non-specific interstitial pneumonia; p.m., post mortem; PAP, pulmonary alveolar proteinosis; UIP, usual interstitial pneumonia.

Table 3 Histology of patients with compound heterozygous ABCA3 mutations

Patient ID	Mutation	Histological picture	Type II** pneumocyte hyperplasia	Alveolar** macrophage accumulation	Interstitial** fibrosis	Alveolar** septal thickening	Electron dense bodies	Age at biopsy (years)
24	p.P193S p.G1421R	NSIP, PAP, DIP*	3	3	1	2	ND	0.1
26	p.L268_L269insL p. L1386P	Neonatal PAP					ND	0.1
27	p.R43C p.R208W	DIP	3	2	1	2	ND	1.5
28	p.P32S p.G1314E	NSIP, DIP*	3	3	2	2	ND	3
30	p.R280H p.R1305L	Diffuse alveolar damage, intra-alveolar fibrinous exudate					ND	0
31	p.R709W p.I1193M	PAP					ND	36
34	p.L798P p.R1612P	CPI	2	1	0	1	ND	0.1
36	p.A1046E p.A1338T p.DelEx29	CPI, increased eosinophils	3	3	2	3	Yes	0.3
38	p.L579P p. R1272Gfs*73	PAP	3	2	0	2	Yes	0.2
39	p.L1584Rfs*49 p.R43L p.R288K	CPI	3	2	0	2	Yes	NA

*Combined picture of; **severity of indicated finding: 0=none, 1=discrete, 2=moderate, 3=strong; severity indicated for available material. CPI, chronic pneumonitis of infancy; DIP, desquamative interstitial pneumonia; NA, not available; ND, not done; NSIP, non-specific interstitial pneumonia; PAP, pulmonary alveolar proteinosis.

supplementary table S8). Staining intensity and pattern were scored in comparison to control tissues. All controls displayed ring-like structures and huge aggregations of ABCA3 protein. By

contrast, staining was weak or absent in patients with ABCA3 mutations. Moreover, aggregates were absent or small and staining pattern was diffuse if present at all. In three patients with null/null

mutations, immunohistochemistry was negative for ABCA3, while two patients with other/other mutations had a moderate staining intensity and at least small ABCA3 aggregates (figure 3, see online supplementary table S8 and supplementary figure S1).

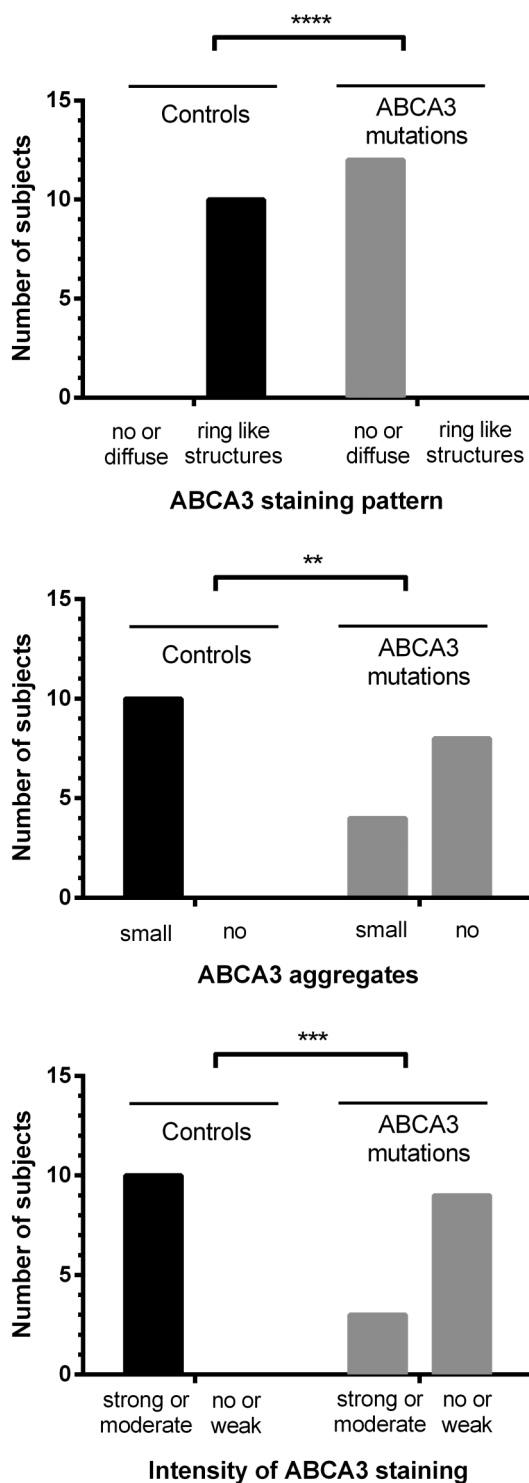


Figure 3 Results of immunohistochemical analysis and semiquantitative scoring in 12 patients after staining for ATP-binding cassette subfamily A member 3 (ABCA3). The hypothesis that frequencies of ABCA3 staining pattern, ABCA3 aggregates and the intensity of ABCA3 staining were different between normal subjects and patients carrying ABCA3 mutations was tested using the Fisher's exact test. ** $p < 0.01$, *** $p < 0.001$, **** $p < 0.0001$.

CXRs in homozygous and in compound heterozygous patients show predominant ground glass, reticular pattern and bronchial wall thickening (the latter two rather increasing with age). In some cases and to a milder degree, cysts, hyperinflation, nodular pattern and consolidation were noted (see online supplementary tables S9 and S10).

Also in the CTs of homozygous and compound heterozygous patients ground glass opacity and reticular pattern were the predominant features, in some cases a mild degree of cysts, bronchial wall thickening, honeycombing, paraseptal emphysema, crazy paving, nodular pattern or consolidation were noted (see online supplementary table S11).

Peripheral bronchial dilatation, resembling bronchiectasis according to the definition by Hansell *et al*,²⁸ was noted especially in homozygous patients <0.1 year, possibly due to severe interstitial lung disease and/or severe mechanical ventilation pressure (see online supplementary tables S9, S11 and supplementary figure S2). In one patient alive at 7 years beginning bronchiectasis was noted with progressive interstitial lung disease (see online supplementary figure S3). Due to the limited number of available investigations in sufficient quality, imaging data have to be interpreted with caution.

DISCUSSION

We characterised the spectrum of lung disease caused by ABCA3 mutations in a cohort of 40 patients with two disease-causing mutations. Of these, 19 mutations have not yet been described to our knowledge. We observed two main phenotypes: patients with early lethal mutations, either (1a) dying within the first 6 months or (1b) before the age of 5 years, and patients with prolonged survival (2) into childhood, adolescence or adulthood (table 1).

The most frequent presentation of ABCA3 mutations in our cohort was neonatal RDS in full-term newborns with fatal outcome. Patients presenting in childhood or later⁹⁻¹¹ had the typical signs and symptoms of chronic interstitial lung disease. Wambach *et al*⁷ recently demonstrated in 185 patients that both, age at presentation and outcome are closely related to the type of mutations (null vs other). The results were confirmed by our data: all patients with null/null mutations presented at birth and died within the first few weeks of life (phenotype group 1a), while some patients with null/other or other/other mutations presented at an older age and survived longer (table 1, figure 2). Thus, while two null mutations seem to be incompatible with life, other mutations can vary significantly in their phenotypical presentation and outcome. However, even identical mutations in siblings are known to vary in phenotype.²⁹ Potential reasons for this variation may be differences in penetrance, epigenetic and environmental factors, and other compensatory mechanisms, possibly within the surfactant system itself.

While PAP is a known histological pattern in ABCA3 mutation, often combined with NSIP or DIP,²¹ the clinical presentation of neonates is frequently labelled as PAP. This was the case in 11 patients of this cohort. They had either white lungs on CXRs or crazy paving pattern on CT scans with respiratory distress despite being born on time. This clinically dominated labelling should be avoided as none of these patients had a pure PAP pattern in histology. Further, clinical presentation of PAP due to mutations in *CSF2RA* is beyond the neonatal period.³⁰ Of interest is patient 31 who carried two likely disease-causing variations in the ABCA3 gene who presented with exercise intolerance and some ground glass opacities on CT scan. She developed the typical features of granulocyte macrophage colony-stimulating factor (GM-CSF) autoantibody positive,

adult PAP and was in remission after treatments with whole lung lavages (see online supplementary table S2, supplement A).

It is further of interest to note that even in the absence of SP-C in BALF patients may survive into adulthood (eg, patients 11 and 12).¹⁰ This suggests that SP-C deficiency may not be the primary disease mechanism in ABCA3 deficiency. On the other hand, the absence of SP-C in BALF may be used as an important indicator for ABCA3 mutations, as has already been suggested by Flamein *et al.*⁸

Additional clinical hints for the presence of ABCA3 mutations are given by radiological and histological investigations (tables 2 and 3, see online supplementary tables S9–S11), although they are not very specific. Immunohistochemical staining pattern and intensity correlates with the type of ABCA3 mutation and survival (figure 3, see online supplementary table S8). Absent staining or abnormal staining pattern (diffuse instead of ring-like) is suggestive of ABCA3 deficiency. Sensitivity and specificity need to be investigated in larger numbers of patients and disease controls.

Efficacy of therapeutic interventions in patients with ABCA3 mutations appears to be poor. Our data showed moderate or sometimes good responses to exogenous surfactant in some patients. Treatment with systemic steroids yielded positive effects in 10/32 patients and hydroxychloroquine in 9/15 patients; most effects were transient and overall survival was low. It is important to recognise that prolonged survival can occur in individuals who do not carry the null/null genotype. One recent report also describes significant improvement including delisting for LTX with the application of triple therapy with intravenous pulse methylprednisolone, and enteral hydroxychloroquine and azithromycin,³¹ suggesting potential efficacy of combination therapy. New therapeutic developments should focus on the underlying mutations and mechanisms. Stop mutations might be addressed with compounds allowing read through,³² whereas missense mutations might be rescued by corrector-type medications.³³ The latter may also be addressed by hydroxychloroquine, although its precise mechanism of action is unknown. In vitro studies identifying appropriate candidates are warranted.

Author affiliations

¹Department of Pediatric Pneumology, Dr. von Hauner Children's Hospital, LMU Munich, Munich, Germany

²Department of Pathology, LMU Munich, Munich, Germany

³Department of Pediatric Radiology, Dr. von Hauner Children's Hospital, LMU Munich, Munich, Germany

⁴Department of Neonatology, Klinikum Großhadern, LMU Munich, Munich, Germany

⁵Department of Pediatric Pneumology, Ankara University Children's Hospital, Ankara University, Ankara, Turkey

⁶Gazi University Hospital, Ankara University, Ankara, Turkey

⁷Pneumology Unit, IRCCS San Matteo Hospital Foundation and University of Pavia, Pavia, Italy

⁸Department of Pediatric Pneumology, University Hospital Leuven, University Leuven, Leuven, Belgium

⁹Department of Neonatology, University Hospital, University Mannheim, Mannheim, Germany

¹⁰Emma Children's Hospital, Academic Medical Center, Amsterdam, Netherlands

¹¹Department of Pediatric Pneumology, Children's Hospital, Lucerne, Switzerland

¹²Department of Pediatrics and Adolescent Medicine, Division of Pediatric Pulmonology and Allergology, Medical University of Graz, Graz, Austria

¹³Department of Pediatric Pneumology and Allergology, Neonatology and Intensive Care, Klinikum Oldenburg, Medical Campus of University Oldenburg, Oldenburg, Germany

¹⁴Clinic of Pediatric Pneumology, Allergology and Neonatology, Hannover Medical School, Hannover, Germany

¹⁵Institute for Clinical Chemistry and Laboratory Medicine, University of Regensburg, Regensburg, Germany

¹⁶Hohentwielstr. 32, 78250 Tengen, Germany

¹⁷Department of Pathology, Academic Teaching Hospital Bielefeld, Bielefeld, Germany

Acknowledgements The authors thank Ms Traudl Wesselak and Andrea Schams for the strong support in collecting and gathering the data. The authors also thank all patients and families for participating in the study, and all members of the ABCA3-study group of the Kids Lung Register for their work and for including patients into the study: P Ahrens, Darmstädter Kinderkliniken Prinzessin Margaret, Darmstadt, Germany; D Aschmann, University Hospital Dresden University, Dresden, Germany; T Berger and N Regamey, Children's Hospital Lucerne, Lucerne, Switzerland; L Chevret, Bicetre Hospital, Le Kremlin Bicetre, France; N Cobanoglu, Ankara University School of Medicine, Ankara University, Ankara, Turkey; JM Cobben, University Hospital, Amsterdam University, Amsterdam, Netherlands; L Donato, University Hospital, Strasbourg University, Strasbourg, France; M Gerstlauer, Klinikum Augsburg, Augsburg, Germany; M Griese, A Irnstetter, M Kappler, M Klemme, C Kröner, F Nagel, M Feilcke, I Pawlita, J Ripper, M Hengst, M Forstner, University Hospital, Munich University, Munich, Germany; K Kristensen, Ringhospitalet, Copenhagen, Denmark; I Campo, M Luisetti, Clinica di Malattie Apparato Respiratoria, Pavia, Italy; E Mildenerberger, University Hospital, Mainz University, Mainz, Germany; G Mostafa and R Weitzdoerfer, University Hospital, Wien University, Wien, Austria; E Eber, A Pfleger, Medical University of Graz, Graz, Austria; L Pinheiro, Hospital Braga, Braga, Portugal; J Pöschl, University Hospital, University Heidelberg, Germany; M Proesmans, UZ Leuven, Leuven, Belgium; J-W Richter, Kinderkrankenhaus auf der Bult, Hannover, Germany; V Rigourd, Institute De Puericulture, Paris, France; K Runge, Klinikum Wuppertal GmbH, Wuppertal, Germany; T Schaible, University Hospital, University Mannheim, Germany; W Schneider, University Hospital, Frankfurt University, Germany; E Cloppenburg, T Hübner, J Seidenberg, Kinderklinik Klinikum Oldenburg, Medizinischer Campus Universität Oldenburg, Germany; T Sismanlar and Ayse T Aslan, Gazi University Hospital, Ankara University, Ankara, Turkey; S C Slood, Amsterdam Medical Center, Amsterdam, Netherlands; N Schwerk, Medizinische Hochschule Hannover, Hannover University, Hannover, Germany; Y Steinrücke, Klinikum Dritter Orden, München, Germany; S Terheggen-Lagro, Emma children's hospital, Academic Medical Center, Amsterdam, Netherlands; S Wagner, Kinderkrankenhaus St Marien, Landshut, Germany; S Wellmann and C Bühler, University Hospital Basel, Basel University, Switzerland; J Wintgens, Staedtische Kliniken Moenchengladbach, Moenchengladbach, Germany; E Fischer and P Lasch, Klinikum Bremen Mitte, Bremen, Germany; H Teschler, Ruhrland Klinik, Essen, Germany; H Schroten, University Hospital, University Düsseldorf, Düsseldorf, Germany.

Contributors MG designed the study, collected the cases, analysed the data and drafted and revised the manuscript. He is the guarantor of the entire manuscript. CK organised and analysed the data and drafted the manuscript. MKI, MH, MKa, NC, TS, ATA, IC, MP, TS, ST-L, NR, EE, JS, NS, CA, CK and MG contributed and evaluated patients and performed chart review. RZ, DR and TW performed laboratory and immunohistochemical analyses, FB and SR performed the histological investigations, VT the radiological investigations. CA and PL performed genetic analysis and contributed to the long-term collection of subjects. All contributors read and critically revised the manuscript and agreed to the final version of the manuscript.

Funding The work of MG was supported by the Deutsche Forschungsgemeinschaft Gr970/8-1, child-EU (FP7, No. 305653) and the "Else Kröner-Fresenius-Stiftung" grant 2013_A72.

Competing interests None declared.

Ethics approval Institutional Review Board (EK 026-06), child-EU (EK 111-13).

Provenance and peer review Not commissioned; externally peer reviewed.

REFERENCES

- Dean M, Rzhetsky A, Allikmets R. The human ATP-binding cassette (ABC) transporter superfamily. *Genome Res* 2001;11:1156–66.
- Allikmets R, Gerrard B, Hutchinson A, *et al.* Characterization of the human ABC superfamily: isolation and mapping of 21 new genes using the expressed sequence tags database. *Hum Mol Genet* 1996;5:1649–55.
- Connors TD, Van Raay TJ, Pety LR, *et al.* The cloning of a human ABC gene (ABC3) mapping to chromosome 16p13.3. *Genomics* 1997;39:231–4.
- Yamano G, Funahashi H, Kawanami O, *et al.* ABCA3 is a lamellar body membrane protein in human lung alveolar type II cells. *FEBS Lett* 2001;508:221–5.
- Ban N, Matsumura Y, Sakai H, *et al.* ABCA3 as a lipid transporter in pulmonary surfactant biogenesis. *J Biol Chem* 2007;282:9628–34.
- Parappil H, Al Baridi A, ur Rahman S, *et al.* Respiratory distress syndrome due to a novel homozygous ABCA3 mutation in a term neonate. *BMJ Case Rep* 2011;2011: pii: bcr1020103427.
- Wambach JA, Casey AM, Fishman MP, *et al.* Genotype-phenotype correlations for infants and children with ABCA3 deficiency. *Am J Resp Crit Care Med* 2014;189:1538–43.
- Flamein F, Riffault L, Muselet-Charlier C, *et al.* Molecular and cellular characteristics of ABCA3 mutations associated with diffuse parenchymal lung diseases in children. *Human Mol Genet* 2012;21:765–75.

- 9 Bullard JE, Wert SE, Whitsett JA, *et al.* ABCA3 mutations associated with pediatric interstitial lung disease. *Am J Respir Crit Care Med* 2005;172:1026–31.
- 10 Campo I, Zorzetto M, Mariani F, *et al.* A large kindred of pulmonary fibrosis associated with a novel ABCA3 gene variant. *Respir Res* 2014;15:43.
- 11 Epaud R, Delestrain C, Louha M, *et al.* Combined pulmonary fibrosis and emphysema syndrome associated with ABCA3 mutations. *Eur Respir J* 2014;43:638–41.
- 12 Coghlan MA, Shifren A, Huang HJ, *et al.* Sequencing of idiopathic pulmonary fibrosis-related genes reveals independent single gene associations. *BMJ Open Respir Res* 2014;1:e000057.
- 13 Brasch F, Schimanski S, Mühlfeld C, *et al.* Alteration of the pulmonary surfactant system in full-term infants with hereditary ABCA3 deficiency. *Am J Resp Crit Care Med* 2006;174:571–80.
- 14 Shulenin S, Noguee LM, Annilo T, *et al.* ABCA3 gene mutations in newborns with fatal surfactant deficiency. *N Engl J Med* 2004;350:1296–303.
- 15 Carrera P, Ferrari M, Presi S, *et al.* Null ABCA3 in humans: large homozygous ABCA3 deletion, correlation to clinical-pathological findings. *Pediatr Pulmonol* 2014;49:E116–120.
- 16 Ciantelli M, Ghirri P, Presi S, *et al.* Fatal respiratory failure in a full-term newborn with two ABCA3 gene mutations: a case report. *J Perinatol* 2011;31:70–2.
- 17 Piersigilli F, Peca D, Campi F, *et al.* New ATP-binding cassette A3 mutation causing surfactant metabolism dysfunction pulmonary type 3. *Pediatr Int* 2015;57:970–4.
- 18 Jackson T, Wegner DJ, White FV, *et al.* Respiratory failure in a term infant with cis and trans mutations in ABCA3. *J Perinatol* 2015;35:231–2.
- 19 Tan JK, Murray C, Schultz A. ABCA3 lung disease in an ex 27 week preterm infant responsive to systemic glucocorticosteroids. *Pediatr Pulmonol* 2016;51:E1–3.
- 20 Hallik M, Annilo T, Ilmoja ML. Different course of lung disease in two siblings with novel ABCA3 mutations. *Eur J Pediatr* 2014;173:1553–6.
- 21 Doan ML, Guillerman RP, Dishop MK, *et al.* Clinical, radiological and pathological features of ABCA3 mutations in children. *Thorax* 2008;63:366–73.
- 22 Choi Y, Sims GE, Murphy S, *et al.* Predicting the functional effect of amino acid substitutions and indels. *PLoS ONE* 2012;7:e46688.
- 23 Kumar P, Henikoff S, Ng PC. Predicting the effects of coding non-synonymous variants on protein function using the SIFT algorithm. *Nat Protoc* 2009;4:1073–81.
- 24 Adzhubei IA, Schmidt S, Peshkin L, *et al.* A method and server for predicting damaging missense mutations. *Nat Methods* 2010;7:248–9.
- 25 Tafel O, Latzin P, Paul K, *et al.* Surfactant proteins SP-B and SP-C and their precursors in bronchoalveolar lavages from children with acute and chronic inflammatory airway disease. *BMC Pulm Med* 2008;8:6.
- 26 Kröner C, Reu S, Teusch V, *et al.* Genotype alone does not predict the clinical course of SFTPC deficiency in paediatric patients. *Eur Respir J* 2015;46:197–206.
- 27 Deutsch GH, Young LR, Deterding RR, *et al.* Diffuse lung disease in young children: application of a novel classification scheme. *Am J Respir Crit Care Med* 2007;176:1120–8.
- 28 Hansell DM, Bankier AA, MacMahon H, *et al.* Fleischner Society: glossary of terms for thoracic imaging. *Radiology* 2008;246:697–722.
- 29 Thavagnanam S, Cutz E, Manson D, *et al.* Variable clinical outcome of ABCA3 deficiency in two siblings. *Pediatr Pulmonol* 2013;48:1035–8.
- 30 Hildebrandt J, Yalcin E, Bresser HG, *et al.* Characterization of CSF2RA mutation related juvenile pulmonary alveolar proteinosis. *Orphanet J Rare Dis* 2014;9:171.
- 31 Hayes D Jr, Lloyd EA, Fitch JA, *et al.* ABCA3 transporter deficiency. *Am J Respir Crit Care Med* 2012;186:807.
- 32 Ryan NJ. Ataluren: first global approval. *Drugs* 2014;74:1709–14.
- 33 Wainwright CE, Elborn JS, Ramsey BW. Lumacaftor-ivacaftor in Patients with Cystic Fibrosis Homozygous for Phe508del CFTR. *N Engl J Med* 2015;373:1783–4.